EUS-guided biliary drainage in distal malignant biliary obstruction: a new tool when ERCP fails

Drenagem biliar ecoguiada no câncer biliar distal: uma nova ferramenta na falha da CPRE

Jonas Takada,[1] Everson L.A. Artifon[2]

Summary

Introduction: Most of patients with biliary tract cancer are diagnosed at an advanced stage. EUS-guided biliary drainage (EBD) is an alternative to percutaneous transhepatic or surgical drainage techniques after failure at conventional access by endoscopic retrograde cholangiopancreatography (ERCP). **Objectives:** To evaluate EBD efficacy and safety in patients with malignant biliary obstruction at the Gastrointestinal Endoscopy Department from Hospital das Clínicas of São Paulo University. **Methods:** There were included in our study patients that had a clinical history of obstructive jaundice and failure at biliary drainage by ERCP. EBD was performed under radioscopic control. The efficacy was analyzed according to clinical outcome and improvement in quality of life after the procedure, which was assessed by the application of a quality of life measurement test, and an evaluation of laboratory tests, signs, symptoms and procedure-related complications. **Results:** From April 2010 to September 2011, 32 patients with advanced biliary tract cancer were included in our study. Three (9.4%) patients had technical failure at EBD procedure. Technical success was achieved in 90.6% (29/32) and clinical improvement occurred in 100% (29/29). EUS-guided choledochoduodenostomy was the most common drainage procedure (58.62%). Duodenal self-expandable metallic stents were placed in 7 (21.85%) cases. There were a significant decrease in bilirubin levels ($p < 0.001$) and patients had improvement in quality of life after the procedure ($p < 0.05$). Complications occurred in 6 (18.75%) patients and the median survival was 90 days. **Conclusion:** EBD was an effective and safe procedure with acceptable complication rates, providing significant improvement in quality of life.

Keywords: Endoscopic Ultrasound, Biliary Cancer, Obstruction, Drainage, Palliation.

Resumo

Introdução: A maioria dos pacientes com câncer biliar é diagnosticada em estágio avançado. A drenagem biliar ecoguiada é uma alternativa à drenagem percutânea e à cirurgia derivativa. **Objetivos:** Avaliar a eficácia e a segurança do método em pacientes com necessidade de drenagem biliar e falha da CPRE prévia. **Método:** Foram incluídos pacientes com obstrução biliar maligna e falha do acesso por CPRE convencional. A eficácia foi avaliada pelo sucesso clínico e pela avaliação da qualidade de vida. Avaliação laboratorial e clínica foram estudadas e computadas por teste estatístico. **Resultados:** Entre abril e setembro, 32 pacientes foram incluídos no protocolo. Em três verificou-se insucesso do acesso ecoguiado. O sucesso técnico ocorreu em 90,6% (29/32) e o sucesso clínico em 100% dos casos. Cole-

1. Aluno (Doutorado) da Pós-Graduação em Clínica Cirúrgica do Departamento de Cirurgia da FMUSP. **2.** Orientador Pleno e Professor do Programa de Pós-Graduação em Clínica Cirúrgica do Departamento de Cirurgia da FMUSP, Coordenador do Setor de Endoscopia Biliopancreática (CPRE) do Serviço de Endoscopia do HC-FMUSP e Chefe do Serviço de Endoscopia do Hospital Ana Costa (HAC) – Santos. **Endereço de correspondência:** Everson L. A. Artifon. Rua Guimarães Passos, 260 – apto. 121 – Vila Mariana – CEP 04107-030 - São Paulo – SP/ e-mail: eartifon@terra.com.br. **Recebido em:** 28/02/2013. **Aprovado em:** 12/03/2013.

docoduodenostomia ocorreu em 58,6% e foi o acesso mais frequente da casuística apresentada. A melhora da bilirrubina em 7 dias foi significante ($p<0,001$) e a qualidade de vida foi melhor no seguimento de 30 dias ($p<0,05$). Complicações ocorreram em 6 (18,75%) e sobrevida média foi de 90 dias. **Conclusões:** A drenagem biliar ecoguiada é uma ferramenta importante na falha da CPRE prévia e com índices de complicações aceitáveis.

Unitermos: Ultrassom Endoscópico, Câncer Biliar, Obstrução, Drenagem, Paliação.

Introduction

Most of the patients with biliary tract cancer are diagnosed at an advanced stage of the disease; therefore, they may not be candidates for curative surgical treatment.[1,2] Due to this late diagnosis and lesions extensions, these patients often develop jaundiced at the time of diagnosis. In theses cases, the relief in obstructive jaundice is essential, because untreated biliary stasis can lead to clinical conditions characterized by pruritus, anorexia, impaired liver function, cholangitis and even premature death.[3]

Endoscopic retrograde cholangiopancreatography (ERCP) with placement of biliary stent is the method of choice for the palliation of obstructive jaundice in these patients with a treatment success rate of 90%.[4] However, ERCP drainage may fail in 5% to 10% of cases, mostly because of altered anatomy, such as tumor stenosis, total gastrectomy, partial gastrectomy with Roux-en-Y reconstruction and bariatric surgery, or failed attempt in conventional cannulation of the major papilla.[5-7]

Percutaneous transhepatic drainage (PTHD) is an alternative method in patients that had a failed ERCP attempt or that are not candidates this procedure. However, PTHD is associated with complications that can reach 30% of the cases, especially biliary fistula, bleeding and liver abscess.[8,9] It is also known that surgical drainage has morbidity and mortality around 30% and 10%, respectively.[2,10]

In a context of minimally invasive procedures, EUS-guided biliary drainage (EBD) is a promising technique that has been recently reported in the literature for patients with failure in ERCP drainage.[11,12] It is performed by the combination of endoscopic ultrasound therapy and ERCP techniques.

In this study, we aim to evaluate the efficacy and the safety of EBD in patients with malignant biliary obstruction after failure in ERCP drainage at a tertiary center in the Gastrointestinal Endoscopy Department from Hospital das Clínicas of São Paulo University. It will also be analyzed technical feasibility and clinical success for this technique, as well as quality of life in patients with malignant biliary obstruction.

Patient and Method

From April 2010 to September 2011, 32 patients with advanced malignant biliary obstruction were included in our study after failure in ERCP drainage. Inclusion criteria were patients over 18 years old, obstructive unresectable cancer of the biliary tract and unsuccessful ERCP drainage, and absence of esophageal or gastric strictures. Exclusion criteria were severe coagulopathy, presence of ascites, and lack of adequate access to biliary tract. Institutional ethics committee approved this study, and all patients provided an informed consent.

Patients were prospectively monitored through scheduled appointments or by telephone contact with the patient or legal guardian in the Department of Gastrointestinal Endoscopy, Hospital das Clínicas, University of São Paulo. The analysis was based on clinical and laboratory data. These data were evaluated before the EUS-guided procedure, and 7, 30, 60 and 90 days after it. At the time of eventual deaths during the follow-up, data were compiled for survival analysis.

The Short Form Survey (SF-36) from Medical Outcomes Study defined quality of life measurement.[13] Technical success was characterized by successful biliary stent placement. Clinical success occurred when there was 50% reduction in total bilirubin from prior baseline level in seven days after the procedure.

A single expert performed all endoscopic procedures. Sedation was done under intravenous midazolam (0.05 mg/kg) associated with fentanyl (2 mcg/kg) as an initial dose followed by controlled infusion of propofol (1.5 mg/kg for induction). Prophylactic antibiotics were used before the procedure.

After unsuccessful therapeutic ERCP, biliary tract was accessed using a linear echoendoscope (GFUCT 240, Olympus, Tokyo, Japan). Color Doppler US was used to identify the vascular anatomy. The dilated bile duct was punctured with a 19-gauge needle (EUSN-19-T, Cook Endoscopy, Winston-Salem, NC, USA). The puncture site was chosen based on EUS evaluation, in a bile duct portion above the tumor, through stomach, duodenal bulb or intestinal loop. To confirm successful biliary access, bile was aspirated and iodine contrast was injected under fluoroscopy view to demonstrate biliary opacification.

Then, a 0.035-inch guidewire was introduced through the EUS needle channel. An attempt was performed to bypass the guidewire through the lesion to reach the duodenal loop as a rendezvous maneuver.

If it was unsuccessful, the needle was withdrawn and a wire-guided needle knife (KD-441Q, Olympus, Tokyo, Japan) was inserted to increase the orifice in the gastrointestinal wall. To complete the biliary drainage, a partially covered self-expandable metallic stent (60x10mm or 80x10mm; WallFlex, Boston Scientific, Natick, MA, USA) was passed over the guidewire. In cases with pyloric or duodenal stenosis, enteral self-expandable metallic stents were placed under same procedure. EBD was characterized as EUS-guided anterograde drainage, rendezvous, hepatogastrostomy, hepatojejunostomy, choledochoduodenostomy, or choledochoantrostomy.

Statistical Analysis

Laboratory tests and quality of life scores were described according to the time of evaluation with use of summary measures (mean, standard deviation, median, minimum and maximum) and it was also assessed normal probability distribution for each parameter using Kolmogorov-Smirnov test.[14] Occasional chance was not accepted ($p<0.05$) in any of the time points. For parameters with statistical significance, the analysis was followed by Bonferroni multiple comparisons in order to find out in what moments occurred between the differences in the variables of examinations and quality of life.[15] The choice of a parametric model with non-normal distribution rather than nonparametric comparisons was decided due to the large amount of deaths that may occur in this type of patient. We used Kaplan-Meier function to estimate the mean and median survival of patients after surgery.[16] The tests were performed at a significance level of 5%.

Results

There were included in our study 32 patients with failure in ERCP biliary drainage. The main causes of failure in ERCP drainage were inability of conventional cannulation of the major duodenal papilla in 65.6% (21/32), and infiltration of the major duodenal papilla in 15.6% (5/32) cases (Table 1).

Table 1. Patient's baseline characteristics, EBD techniques, cholestasis laboratory results before and 7 days after the procedure.

Patient	Age (y)	Sex	Tumor characteristics	TB (mg/dl)	AP (U/L)	GGT (U/L	EBD technique	TB * (U/L)	AP * (U/L)	GGT * (U/L)
1	46	F	Cholangiocarcinoma	13.5	540	350	Hepatogastrostomy	2.2	110	88
2	88	F	Pancreatic cancer	15.5	610	430	Choledochoduodenostomy	3.0	118	75
3	75	M	Metastatic lesion	27.12	1671.4	575	Hepatogastrostomy	2.5	76	92
4	52	M	Pancreatic cancer	8.4	410	345	Choledochoduodenostomy	3.7	110	112
5	41	F	Cholangiocarcinoma	-	-	-	Failed EBD	-	-	-
6	64	M	Cholangiocarcinoma	22.8	1100	880	Hepatogastrostomy	2.9	120	98
7	77	F	Pancreatic cancer	10,7	738	362	Choledochoantrostomy	3.4	169	98
8	95	F	Pancreatic cancer	15.5	486	233	Choledochoduodenostomy	2.8	123	80
9	59	M	Pancreatic cancer	16.93	545	330	Choledochoduodenostomy	3.8	176	130
10	75	F	Cholangiocarcinoma	17.7	1429	461	Choledochoduodenostomy	5.4	207	158
11	74	M	Pancreatic cancer	16.82	1322	923	Anterograde drainage + Enteral stent	3.2	128	102
12	34	F	Pancreatic cancer	11.67	1400	928	Anterograde drainage + Enteral stent	4.1	165	96
13	91	F	Pancreatic cancer	14.59	479	263	Choledochoduodenostomy	2.85	116	83
14	73	M	Pancreatic cancer	16.27	868	611	Choledochoduodenostomy	6.0	203	176
15	85	F	Pancreatic cancer	3.54	1400	887	Choledochoduodenostomy	2.9	132	89
16	34	M	Pancreatic cancer	18.46	1281	743	Choledochoduodenostomy	2.75	109	78
17	70	F	Hepatocarcinoma	11.2	994	538	Choledochoduodenostomy	2.85	97	81
18	59	M	Pancreatic cancer	7.85	658	389	Choledochoduodenostomy	5.1	209	187
19	71	F	Pancreatic cancer	14.2	944	506	Choledochoduodenostomy + Enteral stent	3.4	154	106

Patient	Age (y)	Sex	Tumor characteristics	TB (mg/dl)	AP (U/L)	GGT (U/L	EBD technique	TB * (U/L)	AP * (U/L)	GGT * (U/L)
20	86	F	Pancreatic cancer	8.2	464	478	Choledochoduodenostomy + Enteral stent	2.95	147	109
21	52	F	Pancreatic cancer	19.2	473	312	Choledochoantrostomy	5.6	317	254
22	65	M	Pancreatic cancer	6.9	487	378	Choledochoduodenostomy	2.7	210	123
23	81	M	Cholangiocarcinoma	4.4	1189	784	Hepatogastrostomy	3.6	153	113
24	67	F	Metastatic lesion	11.24	656	411	EUS-guided rendezvous	4.7	193	124
25	81	F	Metastatic lesion	13.5	292	642	Hepatogastrostomy	3.1	160	112
26	55	M	Hepatocarcinoma	9.76	1362	340	Hepatogastrostomy	4.4	402	138
27	56	F	Cholangiocarcinoma	18.86	672	498	EUS-guided rendezvous	9.8	321	345
28	79	F	Gallbladder cancer	-	-	-	Failed EBD	-	-	-
29	81	M	Hepatocarcinoma	-	-	-	Failed EBD	-	-	-
30	77	M	Pancreatic cancer	25	865	473	Choledochoduodenostomy + Enteral stent	15.7	527	345
31	51	M	Pancreatic cancer	11.12	1380	366	Choledochoduodenostomy	5.5	567	198
32	51	M	Pancreatic cancer	17.6	442	662	Choledochoduodenostomy + Enteral stent	2.5	NR	NR

TB – Total bilirubin; AF – Alkaline phosphatase; GGT – Gamma-glutamyl transferase; NR – Normal range value.
*** Results 7 days after the procedure.**

A total of 3 (9.4%) patients had failure in EUS-guided biliary drainage. Technical success in EUS-guided biliary drainage was 90.6% (29/32) with clinical success of 100% (29/29) of them. The procedure was completed in 29 (90.6%) patients by the following techniques: 17 (58.6%) choledochoduodenostomies, 6 (20.7%) hepatogastrostomies, 2 (6.9%) anterograde drainages, 2 (6.9%) choledochoantrostomies, 1 (3.4%) hepatojejunostomies, and 1 (3.4%) EUS-guided rendezvous (Figures 1 and 2).

Figure 1: Image seguence of a EUS-guided hepatogastrostomy. A: Dilated intrahepatic bile duct; B: Doppler EUS of bile duct; C: EUS-guided puncture; D: Cholangiography demonstrating a malignant biliary stricture; E: Fistula enlargement with a needle-knife catheter; F: Self-expandable metallic stent placement; and G: Endoscopic view of the metallic stent.

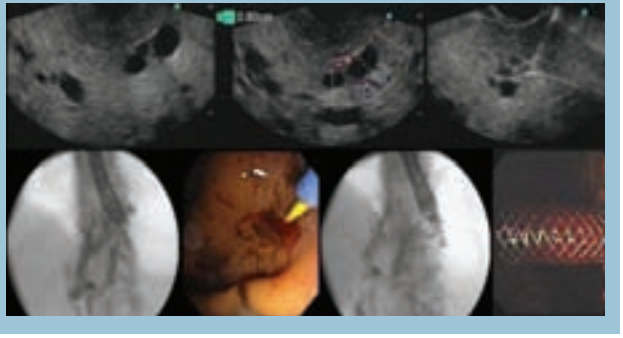

Figure 2: Image sequence of a EUS-guided choledochoduodenostomy. A: Dilated extrahepatic biliary tree; B: EUS-guided puncture; C and D: Cholangiography demonstrating a malignant biliary stricture; E: Fistula enlargement with a needle-knife catheter; F: Fluoroscopy control of the biliary self-expanded metallic stent placement; G: Endoscopic view of metallic stent; and H: Fluoroscopy view of the biliary and duodenal stents.

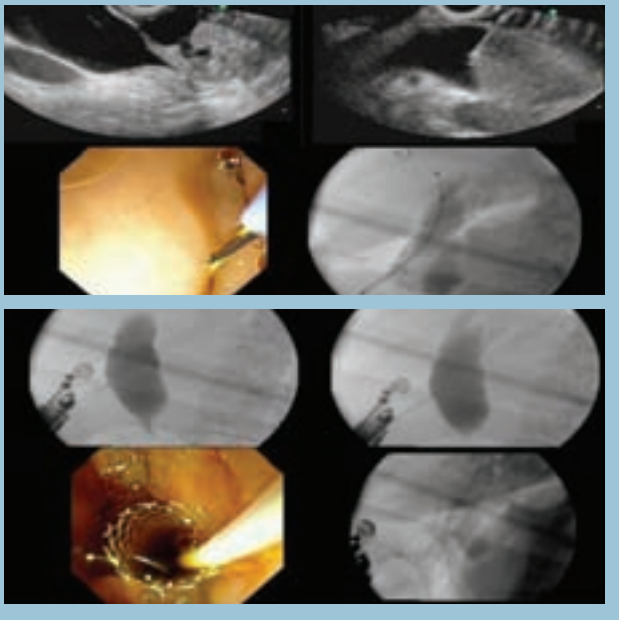

Enteral stent placement was necessary in 7 cases (21.75%). The average diameter of the bile duct at the time of the procedure was 20.49 mm and the mean procedure time was 47 minutes. In all cases, we opted for partially covered self-expanded metallic stent.

Complications occurred in 6 (18.75%) patients. One developed severe abdominal pain after the procedure and promptly responded to analgesia. Two had bleeding at the proximal stent site placement and they were treated successfully with epinephrine solution injection and argon plasma.

Early biliary fistula occurred in 1 patient, in which only conservative treatment was necessary. In one patient an early migration of biliary stent occurred and he was referred to surgery correction. A graft migration occurred in one patient as a result of a late complication, in this case conservative treatment was effective, since the fistula tract was already formed.

In laboratory tests and over the time points accessed, all patients demonstrated a statistically significant improvement in parameters, such as, total bilirubin, gamma-glutamyl transferase, alkaline phosphatase, and leukocytes count ($p<0.05$).

Through the evaluation of the SF-36 questionnaire, the mean scores obtained after seven, 30, 60 and 90 days post-procedure demonstrated a statistically significant increase ($p<0.05$) scores, in all quality of life domains, and the smallest increase occurred in the EGS field (Graphics 1 and 2).

Graphic 1: Mean scores obtained with Quality of Life/ SF-36 questionnaire.

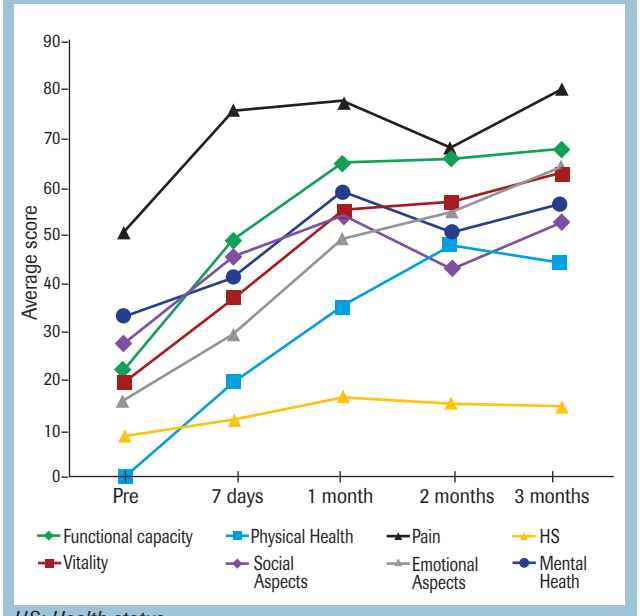

HS: Health status.

Graphic 2: Kaplan-Meier survival function after EBD procedure.

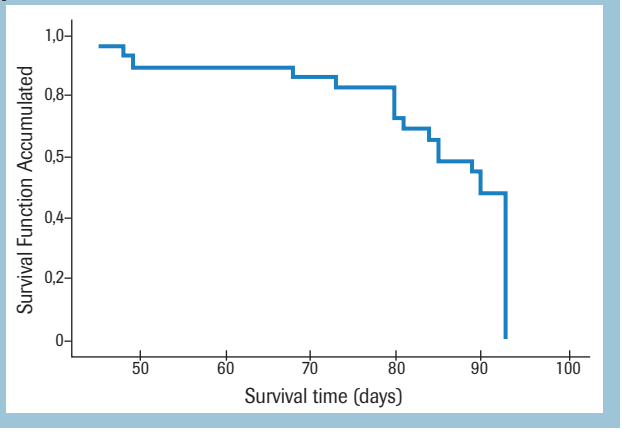

Discussion

The new technique of EBD has been an alternative method to percutaneous transhepatic and surgical drainage procedures in cases of ERCP drainage failure. Some EBD characteristics may be reported:[17,18]

- This is a minimally invasive technique that can be performed in the single procedure, reducing the length of hospital stay, costs and inconvenience to the patients;
- When compared to classical alternatives, such as PTHD and surgery, the EBD appears to be more physiological by enabling an immediate and less invasive internal biliary drainage;
- Endoscopic ultrasound with the utilization of color Doppler features optimizes the safety profile of EBD due to real-time assessment of adjacent structures, especially blood vessels;
- Precise control of the puncture provides a larger and more secure access to the bile duct than the classical alternatives nominated percutaneous biliary drainage and surgery derivative; and
- EBD may not be limited in case of ascites or mild obesity.

In previous reports, it was difficult to accurately individualize success rates of EBD, since the authors described the success of transmural drainage techniques as a rescue procedure in cases of rendezvous or anterograde drainages failure.[19,20]

Since there is a higher technical difficulty of the guidewire progression into the intrahepatic bile ducts, comparisons between extra and intrahepatic approaches should be evaluated separately. Kim et al. used EUS-guided rendezvous technique in 15 patients with distal malignant biliary obstruction and failure of ERCP drainage, and obtained technical success in 12 (80%) cases.[21]

However, when EUS-guided rendezvous and anterograde techniques were combined with transmural techniques, the success rate of endoscopic drainage was 92.55% and the overall complication rate was 4%, including: biliary fistula, pneumoperitoneum, abdominal pain and pancreatitis. In our study, complications occurred in 6 (18.75%) patients: 1 (3.4%) abdominal pain, 2 (6.9%) bleedings, 1 (3.4%) biliary fistula, and 1 (3 4%) late migration of biliary stent.

Recently, Kahaleh et al. reported the largest case series about EBD with a success rate of 84% (41/49) and minor complications in 16% (8/49).[12] Thirty-five patients underwent intrahepatic approach, with a success rate of 83% (29/35). Fourteen patients underwent extrahepatic approach, which was successful in 86% (12/14) of them. In our series, the most used drainage technique were choledochoduodenostomy in 17 (58.62%) patients and hepatogastrostomy in 6 (20.68%). We observed an overall success rate of 90.6% 29/32.

Comparing choledochoduodenostomy with hepatogastrostomy, it is noticed that the extrahepatic biliary tree offers a more evident and feasible access for the fine needle EUS-guided puncture, since that, in the duodenal bulb, the echoendoscope is in a more stable position.[22,23]

In other hand, in the hepatogastrostomy technique, the echoendoscope is positioned in a straightened position, which favors the transmission of force along the axis of the working channel during the stent placement, combined with the fact that the liver parenchyma soft consistency (except in cases with underlying cirrhosis) also offers less resistance to the stent placement, a fact that does not occur in a thick fibrous wall of the common bile duct.[24]

The utilization of appropriated equipment is crucial to the success of this challenging procedure.[22] It could be used a linear array echoendoscope with a working channel of at least 3.2 mm. However, we recommend a therapeutic echoendoscope with a large channel (3.7 or 3.8 mm). The puncture duct access is usually performed with a 19 or 22-gauge needle. In general, a 19-gauge needle is preferred because it accommodates a 0.035-inch guidewire, which enables a better control during endoscopic manipulation of the biliary tract. In this study, we used a 19-gauge needle, 0.035-inch guidewire and needle-knife catheter to enlarge the bilioenteric channel.

We should also notice that, in the clinical point of view, the most relevant technical decision seems to be the type of stent used.[25] In literature, Artifon et al. published the first case of EUS-guided hepatogastrostomy using a self-expanded metallic stent for transmural recanalization in a patient with malignant biliary obstruction, which presented clinical improvement at follow-up of three months.[26]

Although there are no studies comparing stents types (plastic or metallic), the self-expanded metallic stents are preferred for three main reasons: a) when fully expanded, it effectively seals the transmural channel and may prevent from leakage; b) its larger diameter offers greater long-term patency, which reduces the need for stent exchange; c) if there is stent dysfunction caused by tumor ingrowth or clogging, the management is somewhat less challenging than if it were plastic stents, once a new stent (plastic or metallic) can be easily inserted through the previously positioned occluded metallic stent. However, these advantages of metallic stents must be balanced by its limiting factors, such as cost and availability.

In this present study, complications were mild and they did not alter the favorable clinical outcome of biliary drainage procedure, once the quality of life was significantly better after the procedure (7, 30, 60 and 90 days) and remained sustained until the patients last evaluation at three months.

We emphasize the fact that comparative studies of EBD with surgical bypass or percutaneous transhepatic drainage are fundamental. The contribution of EBD for palliation in malignant biliary obstruction led to the conclusion that it is an effective and safe procedure, given its clinical and technical success rates.

Referências

1. Bergasa NV. Medical palliation of the jaundiced patient with pruritus. Gastroenterology clinics of North America 2006; 35(1): 113-23.
2. Boring CC, Squires TS, Tong T, Montgomery S. Cancer statistics, CA: a cancer journal for clinicians 1994; 44(1): 7-26.
3. Hatfield AR. Palliation of malignant obstructive jaundice--surgery or stent? Gut 1990; 31(12): 1339-40.
4. Huibregtse K KM. Endoscopic retrograde cholangiopancreatography, endoscopic sphincterotomy and endoscopic biliary and pancreatic drainage. Textbook of gastroenterology. Philadelphia: J.B. Lippincott, 1995: 2590-617.
5. Kumar S, Sherman S, Hawes RH, Lehman GA. Success and yield of second attempt ERCP. Gastrointestinal endoscopy 1995 May; 41(5): 445-7.

6. Wright BE, Cass OW, Freeman ML. ERCP in patients with long-limb Roux-en-Y gastrojejunostomy and intact papilla. Gastrointestinal endoscopy 2002; 56(2): 225-32.

7. Martin DF. Combined percutaneous and endoscopic procedures for bile duct obstruction. Gut 1994; 35(8): 1011-2.

8. Ferrucci JT, Mueller PR, Harbin WP. Percutaneous transhepatic biliary drainage: technique, results, and applications. Radiology 1980; 135(1): 1-13.

9. Harbin WP, Mueller PR, Ferrucci JT. Transhepatic cholangiography: complicatons and use patterns of the fine-needle technique: a multi-institutional survey. Radiology 1980; 135(1): 15-22.

10. Trede M. Treatment of pancreatic carcinoma: the surgeon's dilemma. The British journal of surgery 1987; 74(2): 79-80.

11. Wiersema MJ, Sandusky D, Carr R, Wiersema LM, Erdel WC, Frederick PK. Endosonography-guided cholangiopancreatography. Gastrointestinal endoscopy 1996; 43(2 Pt 1): 102-6.

12. Kahaleh M, Hernandez AJ, Tokar J, Adams RB, Shami VM, Yeaton P. Interventional EUS-guided cholangiography: evaluation of a technique in evolution. Gastrointestinal endoscopy 2006; 64(1): 52-9.

13. Ware JE, Snow KK, Kosisnki M, Gandek B. SF-36 Health Survey Manual and Interpretation Guide. Boston: The Health Institute, 1993.

14. Kirkwood BR, Sterne JAC. Essential medical statistics. 2. ed. Massachusetts: Blackwell Science 2006; 502.

15. Neter J, Kutner MH, Nachtsheim CJ, Wasserman W. Applied linear statistical models. 4. ed. Ilinois: Richard D. Irwing 1996; 1408.

16. Kleinbaum DG. Survival analysis: a self-learning text. 1. ed. New York: Springer 1996. 324p.

17. Giovannini M, Moutardier V, Pesenti C, Bories E, Lelong B, Delpero JR. Endoscopic ultrasound-guided bilioduodenal anastomosis: a new technique for biliary drainage. Endoscopy 2001; 33(10): 898-900.

18. Gupta K, Mallery S, Hunter D, Freeman ML. Endoscopic ultrasound and percutaneous access for endoscopic biliary and pancreatic drainage after initially failed ERCP. Reviews in gastroenterological disorders 2007; 7(1): 22-37.

19. Mallery S, Matlock J, Freeman ML. EUS-guided rendezvous drainage of obstructed biliary and pancreatic ducts: Report of 6 cases. Gastrointestinal endoscopy 2004; 59(1): 100-7.

20. 20. Maranki J, Hernandez AJ, Arslan B, Jaffan AA, Angle JF, Shami VM, et al. Interventional endoscopic ultrasound-guided cholangiography: long-term experience of an emerging alternative to percutaneous transhepatic cholangiography. Endoscopy 2009; 41(6): 532-8.

21. Kim YS, Gupta K, Mallery S, Li R, Kinney T, Freeman ML. Endoscopic ultrasound rendezvous for bile duct access using a transduodenal approach: cumulative experience at a single center. A case series. Endoscopy 2010; 42(6): 496-502.

22. Perez-Miranda M, de la Serna C, Diez-Redondo P, Vila JJ. Endosonography-guided cholangiopancreatography as a salvage drainage procedure for obstructed biliary and pancreatic ducts. World journal of gastrointestinal endoscopy 2010; 2(6): 212-22.

23. Püspök A, Lomoschitz F, Dejaco C, Hejna M, Sautner T, Gangl A. Endoscopic ultrasound guided therapy of benign and malignant biliary obstruction: a case series. The American journal of gastroenterology 2005; 100(8): 1743-7.

24. Artifon ELA, Ferreira FC, Sakai P. Endoscopic ultrasound-guided biliary drainage. Korean journal of radiology : official journal of the Korean Radiological Society; 13 Suppl 1:S74-82.

25. Kida M, Miyazawa S, Iwai T, Ikeda H, Takezawa M, Kikuchi H, et al. Endoscopic management of malignant biliary obstruction by means of covered metallic stents: primary stent placement vs. re-intervention. Endoscopy 2011; 43(12): 1039-44.

26. Artifon ELA, Chaves DM, Ishioka S, Souza TF, Matuguma SE, Sakai P. Echoguided hepatico-gastrostomy: a case report. Clinics 2007; 62(6): 799-802.