

Pulsed radiofrequency on dorsal root ganglia for chronic pain

Luis Fernando Moura da Silva Junior¹, Daniel Benzecry de Almeida², Laura Moeller³, Renato Endler Iachinski⁴, Lucas Alves Aurich⁵, Ricardo Ramina⁶

Instituto de Neurologia de Curitiba (INC), Curitiba, PR, Brazil.

ABSTRACT

Objective: Evaluate clinical outcome of dorsal root ganglia (DRG) pulsed radiofrequency (PRF) treatment in neuropathic pain of patients with radiculopathy regarding improvement of pain and degree of patients' satisfaction. **Method:** Forty-five procedures in cervical and lumbosacral spine. Data collected by phone call interviews (independent researcher). Evaluation done after one month and at minimum three months follow-up. Analyzed data included objective and subjective improvement, and degree of satisfaction. **Results:** Outcome much better in 31%, 36% better, 24% unchanged, 9% worse. At initial evaluation, relief was rated: 24% excellent, 16% good, 27% moderate, 33% poor. At late evaluation, 27% excellent, 18% good, 7% moderate, 49% poor. Degree of satisfaction was high (82% of patients reported they certainly or probably would repeat the procedure). **Conclusion:** PRF was effective and safe in selected patients. Most patients were satisfied and would repeat/recommend the procedure.

KEYWORDS

Pain, pain intractable, ganglia spinal, radiculopathy.

RESUMO

Radiofrequência pulsada no gânglio da raiz dorsal para tratamento de dor crônica

Objetivo: Avaliar a evolução clínica do tratamento com radiofrequência pulsada (RFP) de gânglio da raiz dorsal (GRD) na dor neuropática em pacientes com radiculopatia, considerando melhora da dor e grau de satisfação dos pacientes. **Método:** Quarenta e cinco procedimentos na coluna cervical e lombossacra. Os dados foram coletados por meio de entrevistas telefônicas (pesquisador independente). Avaliação inicial feita após um mês e final no mínimo de três meses de acompanhamento. Dados analisados incluíram melhora objetiva, subjetiva e o grau de satisfação. **Resultados:** Evolução "muito melhor" em 31%, "melhor" em 36%, "inalterado" em 24%, "pior" em 9%. Na avaliação inicial: 24% "excelente", 16% "bom", 27% "moderada", 33% "pobre". Na avaliação final, 27% "excelente", 18% "bom", 7% "moderada", 49% "pobre". O grau de satisfação foi elevado (82% dos pacientes relataram que certamente ou provavelmente repetiriam o procedimento). **Conclusão:** RFP foi eficaz e segura em pacientes selecionados. A maioria dos pacientes ficou satisfeita e repetiu/recomendou o procedimento.

PALAVRAS-CHAVE

Dor, dor intratável, gânglios espinais, radiculopatia.

- 1 Neurosurgeon, Neurosurgical Department, Instituto de Neurologia de Curitiba (INC), Curitiba, PR, Brazil.
- 2 Neurosurgeon, director of Pain Management Group, INC, Curitiba, PR, Brazil.
- 3 Rheumatologist, Pain Management Group, INC, Curitiba, PR, Brazil.
- 4 Neurologist, INC, Curitiba, PR, Brazil.
- 5 Neurosurgery resident, Neurosurgical Department, INC, Curitiba, PR, Brazil
- 6 Neurosurgeon, chairman of Neurosurgical Department, INC, Curitiba, PR, Brazil.

Introduction

Chronic pain syndrome is a major health problem affecting 2%-40% of the adult population significantly decreasing the quality of life and causing economic losses.^{1,2} Back pain is one of the most common medical conditions, affecting 54%-80% of individuals during their lifetime, whether nociceptive or neuropathic.³ Neuropathic pain is related to an injury or dysfunction of the central or peripheral nervous system.⁴ In spinal diseases the occurrence of anatomical or functional root disturbances is common.

The number of surgical procedures to the spine is increasing, however, they don't seem to decrease the incidence of chronic pain symptoms nor improve the quality of life of those surgically treated, even after multiple surgeries.⁵ Although many types of drugs have been used for conservative treatment of chronic pain, the majority of patients were unable to significantly control their pain.

Minimally invasive procedures, such as radiofrequency (RF) and pulsed radiofrequency are a valuable therapy and have been studied worldwide.⁶ While conventional radiofrequency uses a high temperature ablation, causing thermal damage to the neural structures, pulsed radiofrequency has been shown to cause minimal neural injury and can be used in peripheral nerves, roots and dorsal root ganglia, without major damage. Most initial studies show a possible neuro-modulatory effect following the application of pulsed radiofrequency to the dorsal root ganglia (DRG).⁷ It has, therefore, been an attractive option for the treatment of refractory neuropathic pain, especially in patients with associated root lesions.

The goal of this study was to review the clinical results of pulsed radiofrequency treatment of DRG in patients with neuropathic pain in one or multiple radicular levels. The authors analyzed the degree of pain control and also evaluated the level of satisfaction with this treatment.

Methods

Patients

The authors analyzed patients submitted to pulsed radiofrequency of the DRG for the treatment of chronic pain due to osteoarthritis with radicular compression or failed back syndrome with radicular pain. All patients suffered from neuropathic pain that was refractory despite conservative treatment. The level of the DRG to be treated was determined based on clinical history,

physical examinations and imaging in most cases, particularly in patients with postoperative radiculopathy. In those patients where a specific level could not be clearly defined, a diagnostic block was performed.

Forty-five procedures were performed at the Department of Pain Management, at the Instituto de Neurologia de Curitiba, from December 2006 to April 2010. From this group, 32 were women and 13 were men with ages ranging from 32 to 82 (mean 56.4 years). In 40 cases the target was a lumbosacral DRG and in 5 cases cervical.

Technique

The procedure was performed under fluoroscopic guidance using the Sluiter technique⁸ to reach the target. To achieve perfect needle positioning, paresthesias along the expected dermatome should be elicited below a 0.5 V (50 Hz) stimulation threshold. Whenever possible, low impedance (below 400 mA Ohms) was maintained and, whenever needed, 1 ml of saline was injected.

Pulsed radiofrequency was applied using the following parameters: 2 cycles per second, 20 ms each. All procedures were performed using the RFG 1-B Radiofrequency Generator Cosman model. From December 2006 to January 2009, the time of exposure to pulsed radiofrequency was 4 minutes. However, after February 2009, the RF exposure time increased to 10 minutes.

The procedure was performed under local anesthesia plus sedation with low doses of midazolam and fentanyl, enough to decrease the anxiety level, but enabling the patient to fully cooperate with the medical team to achieve correct physiological localization. During the radiofrequency treatment, an anesthesiologist monitored the patients' vital signs. After the procedure, the patients would remain in the hospital for one day, for pain evaluation, even though no major side effects were expected. In addition, acetaminophen was prescribed along with an opioid on an as-needed basis.

The patients were instructed to avoid the use of anti-inflammatory drugs or steroids for 15 days. If treatment were required in more than one level, they were realized in one procedure.

Outcome measures

The data were collected via two phone interviews performed by an independent researcher. The initial evaluation was performed after one month and a late evaluation was performed after a minimum three months. Pain status was provided by the patient using percentages from 0% to 100 (0% = no change,

and 100% = complete resolution of pain). At the initial and late evaluations, the pain control status were classified on a scale of: 0% to 19% poor, 20% to 49% moderate, 50% to 69% good, and 70% to 100% excellent. The late evaluation was realized at a mean time of 20.37 months.

The subjective improvement in pain was additionally classified by the patient in general terms such as: much better, better, unchanged or worse.

Moreover, the patients were asked to rate their degree of satisfaction with the treatment outcome. The two questions were: “If you could go back in time, would you like to repeat the procedure?” and “Would you recommend the same procedure to a family member or friend?” Answers were classified as: certainly would repeat/recommend; probably would repeat/recommend; probably would not repeat/recommend; and certainly would not repeat/recommend.

Results

The subjective evaluation considered patients’ opinion on improvement of pain, as showed in Figure 1, with best results in cervical group. The objective evaluation considered patients’ degree of pain improvement is showed in Figure 2 and also was better in cervical group.

Finally, the satisfaction of patients, showed in Figure 3, was better in cervical group, but also positively relevant in all groups.

There were no complications related to the procedure. No patient had pain worsening or paresthesias. No significant hematoma or infection was observed.

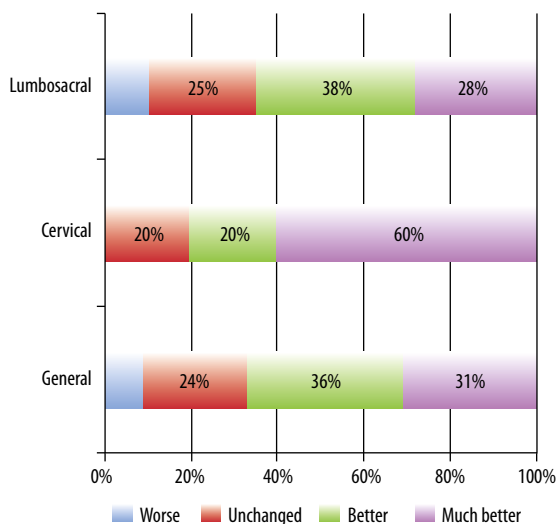


Figure 1 – Patients’ opinion on improvement of pain (subjective).

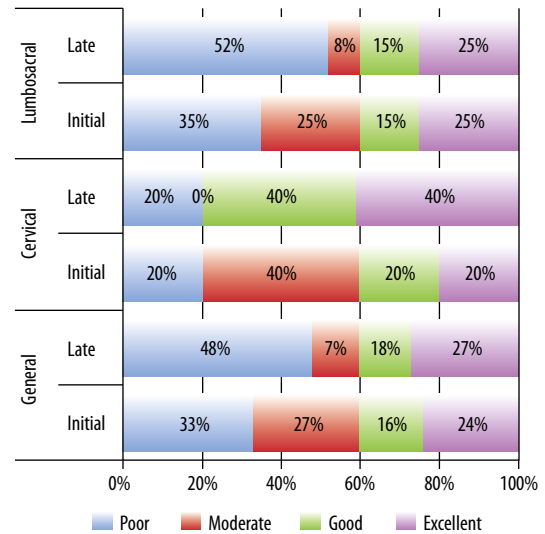


Figure 2 – Patients’ degree of pain improvement (objective).

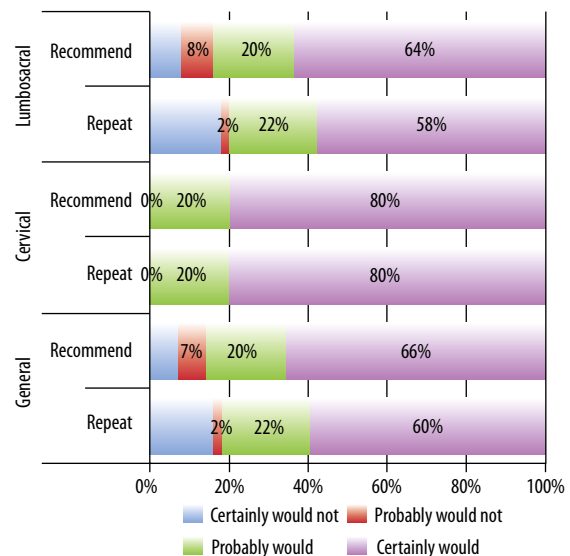


Figure 3 – Subjective evaluation of the results.

Discussion

The use of RF in clinical practice started in the 1950’s, when Rosomoff *et al.*⁹ used this technique to induce spinothalamic lesions during chordotomies. At that time, many authors showed interest in its more predictable thermocoagulation effect, especially in the surgical treatment of trigeminal neuralgia and other painful conditions. With the evolution of RF generators and electrodes, this technique became widespread in the neurosurgical armamentarium.

Pulsed RF became popular after the published series of Slappendel *et al.*,¹⁰ in 1997, which analyzed two groups of patients with cervicobrachial pain. One group

was treated using cervical spine RF at 67° C and the other with a maximum of 40° C. The results were similar in both groups. Although it could be interpreted as if RF was similar to a placebo, the researchers found that both groups obtained a clear benefit in pain improvement. With these observations, it was suggested that many major RF effects could be the result of something else rather than thermal neural ablation.

In patients with neuropathic pain syndromes, and especially when the target was the dorsal root, conventional RF could induce deafferentation.¹¹ With the advent of pulsed RF, major neural structures could be targeted. Considering the importance of DRG as a major region in pain modulation, some authors have studied its role in interventional treatment.

With the advent of pulsed radiofrequency, the question focused on what could influence pain control in a typical radiofrequency procedure besides the thermoablation.¹² Early publications suggested that a beneficial effect was also attributable to neural tissue exposure to electrical stimuli and not only to thermal damage. Initial studies in animals and further investigation in human patients presumed a neurobiological phenomenon changing the transmission on pain stimuli, defining pulsed RF as neuromodulatory method.¹³

Higuchi *et al.*,¹⁴ in 2001, analyzed the results of rats treated with conventional radiofrequency, pulsed radiofrequency or sham applied at the DRG after hemilaminectomy. Immunohistochemical analysis showed an increase of c-Fos immunoreactive neurons on the dorsal root and the spinal cord, especially in superficial laminae (I, II and V). This was found mostly ipsilaterally to the stimulation site and, in a lesser extent, contralaterally, suggesting the occurrence of cellular changes not related to the thermal action itself, but caused by a possible inhibitory activation of interneurons. Van Zundert and Cahana,¹⁵ in 2005, also studied rats treated with pulsed radiofrequency after laminectomy and found similar results after seven days.

More recently, Podhajsky *et al.*¹⁶ observed some anatomopathologic alterations on the nerve rootlet and in the spinal cord in rats that underwent pulsed or conventional RF on DRG. They showed that in the pulsed RF group, there was no visible histologic lesions under optical microscopy examination. Some subclinical changes such as endoneural edema, fibroblasts activation and collagen deposition were observed, which could be related to the activation of a modulatory system.

Another explanation to the analgesic effect of pulsed RF on neuropathic pain is the possible inhibition of neuronal activity, as observed by Cahana *et al.*,¹⁷ in 2003. These authors showed that in cultures of hippocampal cells, exposure to RF promoted neuronal inhibition at synaptic transmission level.

Structural changes in neurons undergoing pulsed radiofrequency seem to be minimal. In 2009, Protasoni *et al.*¹⁸ studied early morphological changes following pulsed radiofrequency under optic and electron microscopy of DRG in order to observe ablative or neuromodulatory signs.

Erdine *et al.*¹⁹ researched the effects of pulsed radiofrequency on the axonal ultrastructure of the sciatic nerve. Contrary to what was observed in the sham group, the study showed morphologic and mitochondrial membrane changes, microfilaments and microtubules rupture and rearrangement, mainly in C-fibers than in A-delta and A-beta fibers, within the specimens of the pulsed radiofrequency group.

In the present series, the authors used percentage values to evaluate pain intensity instead of analyzing any decrease in visual or numeric scales. This was due to the preference of most of the patients evaluated. Some authors agree that there is a good relationship between the percentage pain reduction and the evaluation using numeric rating scale,^{20,21} while some papers suggest a more consistent relationship between the percent change in pain intensity and the clinically important changes.²²

The first study with clinical use of pulsed radiofrequency was published by Sluijter *et al.*,²³ in 1998. In their prospective, but not controlled study, 60 patients were evaluated after treatment with radiofrequency, 36 pulsed and 24 continuous, with a temperature limit of 42°C. At 6 weeks evaluation, 86% of the patients from the pulsed group and 12% from the continuous group showed improvement of more than 50% using the GPE scale.

In another prospective, non-controlled study on pulsed radiofrequency (with 28 patients) published by Shabat *et al.*,²⁴ no anesthetic test block was done, where the correct root level was determined by clinical examination and imaging exams. In addition to pulsed radiofrequency sessions, patients also underwent other treatments. Three months following the procedure, 82% of patients had improved VAS (visual analogic scale) by more than 30%, and 68% of them had achieved a similar benefit after 1 year.

In our study, the cervical subgroup had improvements of more than 50% in 40% of cases in the early evaluation, and 80% in the late evaluation. These results after pulsed radiofrequency were significantly better in cervical than in lumbosacral group.

A prospective, randomized, double-blinded study of 23 patients with chronic cervicobrachialgia using pulsed radiofrequency was published by Van Zundert *et al.*²⁵ In their sample, 11 patients underwent pulsed radiofrequency and 12 were in the *sham* group. At 3-month-evaluation, 9 patients of the radiofrequency group showed improvements of more than 50%, while in the *sham* group, only 3 patients. These results were statistically significant ($p < 0,05$).

Van Zundert *et al.*,²⁶ published another paper on this subject in 2003. It was a retrospective study in chronic single level cervicobrachialgia, with 18 patients. Using the GPE rating scale, 72% of patients experienced improvements of more than 50% in 2 months, 56% maintained this improvement at 3 to 11 months and 33% for periods exceeding one year. The authors conclude, therefore, that treatment with pulsed radiofrequency in the cervical DRG provides satisfactory pain relief in the long term, in most patients with radicular cervicobrachialgia.

Chao *et al.*²⁷ published a study in 2008 of 154 patients with cervical radicular (49 cases) or lumbar (116 cases) pain derived from disc herniation or the failure of previous treatment. In the initial evaluation at 1 week, 53.06% of the cervical group had pain relief exceeding 50%. At 3 months follow-up, 44.83% had improved.

In our study, at the lumbosacral spine, 40% of patients improved by more than 50% at initial evaluation and 40% maintained this improvement in late evaluation. Teixeira *et al.*¹¹ published a retrospective series of 13 patients with radicular pain due to disc herniation. In all cases there was an indication for surgery but the patients were treated with pulsed RF instead. The decision on the root level to be treated was based only on clinical examination and imaging. In this series, 9 patients had motor or sensory deficit related to the root involved. In the evaluation after 1 year, 92% of these patients showed improvement (up to 5 points) in the Pain numerical scale, and surgery was no longer indicated. In all cases, a complete resolution of the initial neurological deficits was observed.

In our study, the authors analyzed the degree of satisfaction with the pulsed radiofrequency treatment, as well as the results. Most patients were satisfied, 67% had at least mild improvements, based on a subjective response. It is worth noting that, regardless of the improvement rate, 82% stated that they would undergo the procedure again as initially proposed. Furthermore, 87% of patients said that they would recommend the procedure to a friend or a relative.

Further considerations should be made about our study, which cannot be evaluated statistically. The first is that we included the most refractory patients, including some with more than two spine operations. In cervical group patients are usually referenced to Pain Group early in treatment than in lumbosacral. So they suffered less time with the pain and underwent few procedures when compared to lumbosacral. Although we could not evaluate this group of patients separately (due to the small number of cases), based on this data, their outcome seemed to be worse.

The study included older patients with spinal stenosis that could not be treated surgically due to clinical issues; most of them had multiple compressions, and

the results of such cases were poor and not statistically relevant.

In the interview, the authors found that some lumbar level patients were not satisfied with the procedure because of residual low back pain, despite having had a marked improvement in their painful neuropathic symptoms and being advertised of the aim of treatment previously to the procedure.

Additionally, it's not clear that longer radiofrequency exposure leads to better results. Further studies should be undertaken to answer these questions.

Conclusion

In our study, pulsed radiofrequency was safe, no complications were seen and achieved satisfactory improvement in neuropathic pain. Better results were found in cervical neuropathic pain than in or lumbosacral region. Most patients were satisfied after the treatment and would repeat or recommend the procedure if indicated. Further studies with longer follow up are needed.

Disclosures

The authors have nothing to disclose.

References

1. Breivik H, Collett B, Ventafridda V, Cohen R, Gallacher D. Survey of chronic pain in Europe: prevalence, impact on daily life, and treatment. *Eur J Pain*. 2006;10(4):287-333.
2. Blyth FM. Chronic pain – is it a public health problem? *Pain*. 2008;137(3):465-6.
3. Manchikanti L, Singh V, Datta S, Cohen SP, Hirsch JA; American Society of Interventional Pain Physicians. Comprehensive review of epidemiology, scope, and impact of spinal pain. *Pain Physician*. 2009;12(4):E35-70.
4. Bouhassira D, Lantéri-Minet M, Attal N, Laurent B, Touboul C. Prevalence of chronic pain with neuropathic characteristics in the general population. *Pain*. 2008;136(3):380-7.
5. Babu MA, Coumans JV, Carter BS, Taylor WR, Kasper EM, Roitberg BZ, et al. A review of lumbar spinal instrumentation: evidence and controversy. *J Neurol Neurosurg Psychiatry*. 2011;82(9):948-51.
6. Chua NH, Vissers KC, Sluijter ME. Pulsed radiofrequency treatment in interventional pain management: mechanisms and potential indications – a review. *Acta Neurochir (Wien)*. 2011;153(4):763-71.
7. Malik K, Benzon HT. Radiofrequency applications to dorsal root ganglia: a literature review. *Anesthesiology*. 2008;109(3):527-42.

8. Sluijter ME. Radiofrequency: a review of radiofrequency procedures in the lumbar region. Amsterdam: FlivoPress; 2001.
9. Rosomoff HL, Brown CJ, Sheptak P. Percutaneous radiofrequency cervical cordotomy: technique. *J Neurosurg.* 1965;23(6):639-44.
10. Slappendel R, Crul BJ, Braak GJ, Geurts JW, Booij LH, Voerman VF, et al. The efficacy of radiofrequency lesioning of the cervical spinal dorsal root ganglion in a double blinded randomized study: no difference between 40 degrees C and 67 degrees C treatments. *Pain.* 1997;73(2):159-63.
11. Teixeira A, Grandinson M, Sluijter ME. Pulsed radiofrequency for radicular pain due to a herniated intervertebral disc – an initial report. *Pain Pract.* 2005;5(2):111-5.
12. Gallagher RM. Pulsed radiofrequency treatment: what is the evidence of its effectiveness and should it be used in clinical practice? *Pain Med.* 2006;7(5):408-10.
13. Cahana A, Van Zundert J, Macrea L, van Kleef M, Sluijter M. Pulsed radiofrequency: current clinical and biological literature available. *Pain Med.* 2006;7(5):411-23.
14. Higuchi Y, Nashold BS Jr, Sluijter M, Cosman E, Pearlstein RD. Exposure of the dorsal root ganglion in rats to pulsed radiofrequency currents activates dorsal horn lamina I and II neurons. *Neurosurgery.* 2002;50(4):850-5.
15. Van Zundert J, Cahana A. Pulsed radiofrequency in chronic pain management: looking for the best use of electrical current. *Pain Pract.* 2005;5(2):74-6.
16. Podhajsky RJ, Sekiguchi Y, Kikuchi S, Myers RR. The histologic effects of pulsed and continuous radiofrequency lesions at 42 degrees C to rat dorsal root ganglion and sciatic nerve. *Spine (Phila Pa 1976).* 2005;30(9):1008-13.
17. Cahana A, Vutskits L, Muller D. Acute differential modulation of synaptic transmission and cell survival during exposure to pulsed and continuous radiofrequency energy. *J Pain.* 2003;4(4):197-202.
18. Protasoni M, Reguzzoni M, Sangiorgi S, Reverberi C, Borsani E, Rodella LF, et al. Pulsed radiofrequency effects on the lumbar ganglion of the rat dorsal root: a morphological light and transmission electron microscopy study at acute stage. *Eur Spine J.* 2009;18(4):473-8.
19. Erdine S, Bilir A, Cosman ER, Cosman ER Jr. Ultrastructural changes in axons following exposure to pulsed radiofrequency fields. *Pain Pract.* 2009;9(6):407-17.
20. Cepeda MS, Africano JM, Polo R, Alcalá R, Carr DB. What decline in pain intensity is meaningful to patients with acute pain? *Pain.* 2003;105(1-2):151-7.
21. Cepeda MS, Africano JM, Polo R, Alcalá R, Carr DB. Agreement between percentage pain reductions calculated from numeric rating scores of pain intensity and those reported by patients with acute or cancer pain. *Pain.* 2003;106(3):439-42.
22. Farrar JT, Polomano RC, Berlin JA, Strom BL. A comparison of change in the 0-10 numeric rating scale to a pain relief scale and global medication performance scale in a short-term clinical trial of breakthrough pain intensity. *Anesthesiology.* 2010;112(6):1464-72.
23. Sluijter ME, Cosman ER, Rittman WB, Van Kleef M. The effects of pulsed radiofrequency fields applied to the dorsal root ganglion: A preliminary report. *Pain Clin.* 1998;11:109-17.
24. Shabat S, Pevsner Y, Folman Y, Gepstein R. Pulsed radiofrequency in the treatment of patients with chronic neuropathic spinal pain. *Minim Invasive Neurosurg.* 2006;49(3):147-9.
25. Van Zundert J, Patijn J, Kessels A, Lamé I, van Suijlekom H, van Kleef M. Pulsed radiofrequency adjacent to the cervical dorsal root ganglion in chronic cervical radicular pain: a double blind sham controlled randomized clinical trial. *Pain.* 2007;127(1-2):173-82.
26. Van Zundert J, Lamé IE, de Louw A, Jansen J, Kessels F, Patijn J, et al. Percutaneous pulsed radiofrequency treatment of the cervical dorsal root ganglion in the treatment of chronic cervical pain syndromes: a clinical audit. *Neuromodulation.* 2003;6(1):6-14.
27. Chao SC, Lee HT, Kao TH, Yang MY, Tsuei YS, Shen CC, et al. Percutaneous pulsed radiofrequency in the treatment of cervical and lumbar radicular pain. *Surg Neurol.* 2008;70(1):59-65.

Correspondence address

Luis Fernando Moura da Silva Jr.
 Rua Jeremias Maciel Perretto, 300, Ecoville
 81210-310 – Curitiba, PR, Brazil
 Phone: +55 41 3028-8580
 E-mail: luisfernando@inc-neuro.com.br