

Accuracy assessment of human sphenoidal sinus volume and area measure and its relationship with sexual dimorphism using the 3D-CT

Avaliação da precisão das medidas de volume e área do seio esfenoidal humano em relação ao dimorfismo sexual utilizando a TC-3D

Jefferson Xavier Oliveira*
Andrea Perrella**
Karina Cecília Panelli Santos***
Marcelo Augusto Oliveira Sales****
Marcelo Gusmão Paraíso Cavalcanti*

Abstract

Introduction – The purpose of this study was to evaluate the precision of volumetric measurements of sphenoidal sinuses and the obtention of sexual dimorphism, using spiral computed tomography (CT). **Materials and Methods** – Fifty individuals were studied (25 male and 25 female), examined with CT multiplanar reconstructions in sagittal and coronal views, and in 3D-CT. The statistical analysis was obtained by using the Levene test, and t-test. **Results** – The method used is over the inadequate limit for area measurements, and the method is acceptable for volume, but needs improvement. Male individuals showed a mean higher than that female's, and a higher variation for area and volume. **Conclusion** – The spiral CT is helpful in sphenoidal sinus region study, showing precision for volume only. There was a significant difference between the mean values of the two genders, so the method can be used to determine sexual dimorphism.

Key words: Sex characteristics; Sphenoid sinus; Tomography, spiral computed/utilization

Resumo

Introdução – O objetivo deste estudo foi avaliar a precisão das medidas de volume e área do seio esfenoidal humano, e a possibilidade de obtenção do dimorfismo sexual. **Materiais e Métodos** – Foram estudados 25 indivíduos do gênero masculino e 25 do feminino, examinados por meio da tomografia computadorizada, com reconstrução em terceira dimensão, e recursos de computação gráfica. A análise estatística foi feita utilizando os métodos de Análise de Variância para medidas repetidas (ANOVA), teste de Levene e teste-t. **Resultados** – O método utilizado está pouco acima do limite de não aceitação, e, quanto ao volume, é aceitável precisando ainda de melhoria. Notamos que o gênero masculino apresenta uma média aparentemente maior que o sexo feminino, bem como uma variação maior tanto em área quanto em volume. **Conclusão** – A tomografia computadorizada em espiral foi útil no estudo da região de seios esfenoidais, apresentando precisão adequada apenas para volume. A diferença significativa entre as médias dos valores dos grupos masculino e feminino possibilita afirmar que há possibilidade de utilização do método para avaliação do dimorfismo sexual.

Palavras-chave: Caracteres sexuais; Seio esfenoidal; Tomografia computadorizada espiral/ utilização

Introduction

There is a significant variation in the structure of the sphenoidal sinus in human skulls, that contributes to the few papers published in the literature defining the sphenoidal configuration and its limits⁴. That was previously

described by Fujioka and Young³ in 1978.

To study the sphenoidal configuration and its aeration many authors used radiological images, ranging from conventional techniques to computed tomography (CT) exams and anatomical specimens.

The use of planigraphy to study sphenoidal sinus was

* PhD, School of Dentistry, University of São Paulo.

** DDS, MSc, School of Dentistry, University of São Paulo.

*** DDS, Specialist in Dental Image. E-mail: kapanelli@hotmail.com

**** PhD, School of Dentistry, Federal University of Paraíba.

emphasized, due to the surgical importance of the septa found in the sphenoidal sinus and the fact that it avoids the overlapping of surrounding structures. Besides that, no significant difference was observed between males and females^{5,8}.

The CT scans can be very important⁴. It is the exam of choice to evaluate patients about to be submitted to surgery treatment, because it offers reliable anatomic references, providing quantitative and qualitative understanding of the sphenoidal structure^{1,4,6}.

Sinus initial expansion, the degrees of aeration over the years, presence of septa within the sinus, bony crests and the basilar extension of the sphenoidal sinus can be evaluated by CT^{4,7,9}.

The relation between male and female sphenoidal sinus was verified by the use of conventional radiographies (lateral and frontal). Males presented a slight preponderance regarding sinus volume and size¹⁰.

It is very important for surgeons to know in detail the three-dimensional anatomical features of the sphenoidal sinus and its surrounding structures in order to avoid complications during sphenoidotomy. The dimensions of the sphenoidal sinus can vary tremendously, so the CT multiplanar reconstruction is useful for treatment planning and can help promote safe performance of a sphenoidotomy due to its precise digital information of the sinus and surrounding structures².

Material and Methods

CT images of 50 patients were analyzed retrospectively, 25 females and 25 males, who were submitted to a multislice computed tomography (Aquilion, Toshiba Medical Inc., Tustin, CA) in the Radiology Department of the Medicine University of Iowa, Iowa City, USA. The acquisition of CT data was performed by the following protocol: a 3 mm-thick slice with 3 mm interval of reconstruction and 1 slice by 1 second time, using 150 kVp and 120 mA, matrix 512 x 512. The data set was sent to the 3D Image Laboratory (Labi-3D) at School of Dentistry, University of São Paulo and transferred to an independent workstation (DELL 520 Precision Windows NT) using a Vitrea™ software (Vital Images Inc., Plymouth, MN, USA).

Axial views and multiplanar reconstructions were used to identify the sphenoidal sinus' greatest diameter (Figure 1). Volumetric measurements were obtained by manual contour in three view plans, using software tools and mouse. Density variations were recognized and area and volume of the structure calculated.

The procedure was carried out twice in different times by two experienced examiners.

The influence of different examiners and the repetition of the measurements they took were checked. The variability of both groups in the Levene test was initially checked to verify gender differences. Repeatability and reproducibility tests were carried out to check the influence of the observers' analysis and analysis repetition at obtained measurements.

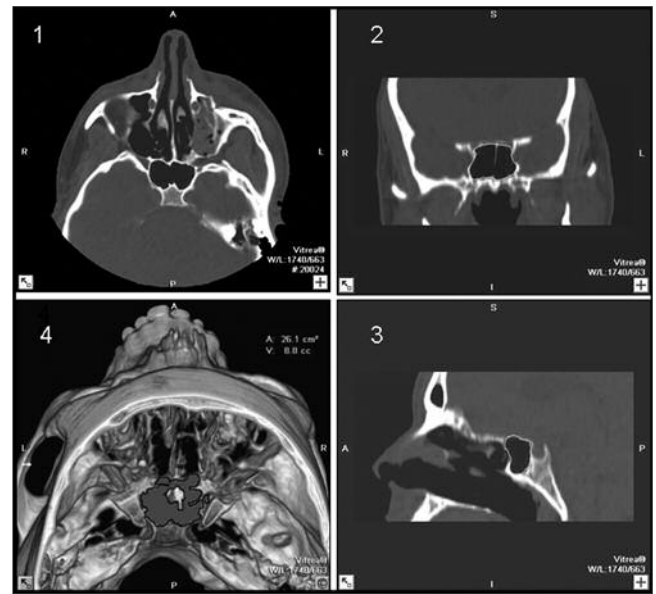


Figure 1. (1) axial view, (2) coronal view, (3) sagittal view, demonstrating the sphenoid sinus limits, (4) 3D-CT image demonstrating volume and area

The t-test was used to compare the mean data of both groups and evaluate the differences.

Results

The results are expressed in Tables 1, 2 and 3, and Graphs 1 and 2.

Table 1 shows the results of Variance Analysis for area measures. It's possible to verify that the analysts' evaluation varies due to patients variation.

Table 2 shows the results of Variance Analysis for volume measures. The results reveal that the observers' data variation is not significant and have no relation to patients' variation. The variation is basically due to analyses repetition.

Table 3 shows the summary of measures for each gender and total data. For area analyses, it shows that the male group presents higher mean value and variation as compared to the female group. One may notice in the female group that they are so different that very high measures and very low measures can be found, in contrast to the male group. Exactly the same can be noticed for volume measures.

Graph 1 shows the comparison between the examiners for area measurement. The measures performed by the examiner "b" are always higher than those from examiner "a".

Graph 2 shows the comparison between the examiners for volume measurement. The measures performed by both examiners trend to be similar.

Variations in each group were first checked separately in order to verify gender differences. The Levene test showed no difference between each group variations, both for volume and area evaluation.

Mean area and volume values were compared by the test-t that indicated significant differences.

Table 1. Variance analysis for area measurement

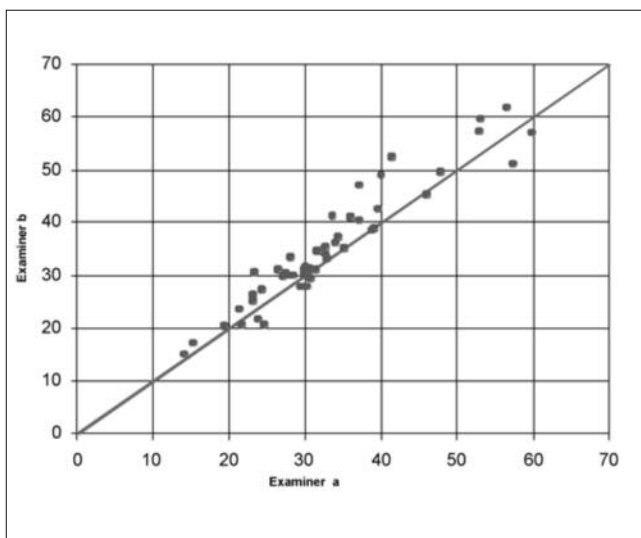
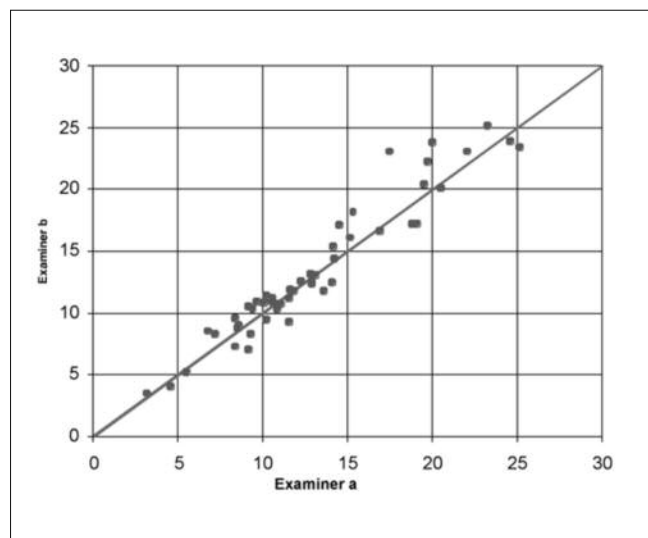
Source of variation	Degrees of freedom	Sum of squares	Mean squares	F Statistics	Descriptive level
Pacient	48	19283.9	401.748	34.8677	0.000
Analyst	1	170.1	170.116	14.7644	0.000
Pacient * analyst	48	553.1	11.522	1.8229	0.006
Repeatability	98	619.4	6.321		
Total	195	20626.5			

Table 2. Variance analysis for volume measurement

Source of variation	Degrees of freedom	Sum of squares	Mean squares	F Statistics	Descriptive level
Pacient	48	5220.19	108.754	62.2964	0.000
Analyst	1	0.65	0.651	0.3732	0.544
Pacient* analyst	48	83.8	1.746	1.3814	0.090
Repeatability	98	123.84	1.264		
Total	195	5428.48			

Table 3. Resume of volume and area measurements

Sex	Mean		Median		Standard deviation		Minimum		Maximum	
	Area	Volume	Area	Volume	Area	Volume	Area	Volume	Area	Volume
Male	37.75	15.40	35.08	14.28	11.17	5.59	16.33	4.30	58.35	24.25
Female	30.32	10.88	29.03	10.45	8.60	3.83	14.63	3.30	59.08	20.28
Total	34.04	13.14	31.09	11.73	10.56	5.26	14.63	3.30	59.08	24.25

**Graphic 1. Comparison between examiners for area measurement****Graphic 2. Comparison between examiners for volume measurements**

Discussion

The necessity of knowing human anatomy has been arisen the interest of specialists. The literature emphasizes the importance of knowing human sphenoidal sinus anatomy, specially its size, internal anatomy, limits and correlation with other structures^{2,4}, but presents low information about it.

The CT represents an important modality to access anatomy virtually, and has been used to evaluate human morphology^{7,9}. CT provides qualitative and quantitative

information about sphenoidal sinus, helping at surgery planning and reduction of risks^{1-2,4,6,8}.

Until 2001, there were reports of CT application only to verify the sphenoidal sinus expansion during an individual's growth and, the presence of septa within the sinus, what may be considered contemporaneousness^{7,9}.

The CT methodology was employed because of the possibilities it offers and all the involved resource, such as precision while analyzing the same sample. There is an excellent correlation between anatomical specimens and the image observed at axial CT images⁴.

According to Levene statistical analysis, there is no significant difference between variability of both genders and, the test t proved that the mean values of both groups are different, for area and volume values.

For area evaluation, the variance analysis' components showed that the method is at an inadequate limit and it must be improved to minimize the error or multiple analyses must be carried out, using mean data as correct. The most significant variations are related to different examiners and analyses repetition.

The variance components for volume showed acceptable results, but indicated that the method must be im-

proved. The reproducibility showed no significant impact and the variation cause was repeatability.

Conclusion

The CT exam with 3D reconstructions and computer graphic methods made possible the sphenoidal sinus study, presenting precision for volume. For area evaluation, however, it needs improvement. The values for males and females were significantly different, proving that this method can be used to evaluate sexual dimorphism.

References

1. Citardi MJ, Gallivan RP, Batra PS, Maurer CR Jr, Rohlfing T, Roh HJ *et al.* Quantitative computer-aided computed tomography analysis of sphenoid sinus anatomical relationships. *Am J Rhinol.* 2004;18(3):173-8.
2. Enatsu K, Takasaki K, Kase K, Jinnouchi S, Kumagami H, Nakamura T *et al.* Surgical anatomy of the sphenoid sinus on the CT using multiplanar reconstruction technique. *Otolaryngol Head Neck Surg.* 2008; 138(2):182-6.
3. Fujioka M, Young LW. The sphenoidal sinuses: radiographic patterns of normal development and abnormal findings in infants and children. *Radiology.* 1978;129(1):133.
4. Haetinger RG, Navarro JA, Liberti EA. Basilar expansion of the human sphenoidal sinus: an integrated anatomical and computerized tomography study. *Eur Radiol.* 2006; 16(9):2092-9.
5. Hammer G, Radberg C. The sphenoidal sinus. An anatomical and roentgenologic study with reference to transsphenoid hypophysectomy. *Acta Radiol.* 1961;56:401-22.
6. Kazkayasi M, Karadeniz Y, Arıkan OK. Anatomic variations of the sphenoid sinus on computed tomography. *Rhinology.* 2005;43(2):109-14.
7. Mutlu C, Unlu HH, Goktan C, Tarhan S, Egrilmez M. Radiologic anatomy of the sphenoid sinus for intranasal surgery. *Rhinology.* 2001;39(3):128-32.
8. Rothman SL, Kier EL, Allen WE. The radiology of transsphenoidal hypophysectomy: a review of 100 cases. *AJR Am J Roentgenol.* 1976; 127(4):601-6.
9. Yonetsu K, Watanabe M, Nakamura T. Age-related expansion and reduction in aeration of the sphenoid sinus: volume assessment by helical CT scanning. *AJNR Am J Neuroradiol.* 2000;21(1):179-82.
10. Zecchi S, Orlandini GE, Gulisano M. [Statistical study of the anatomoradiologic characteristics of the sphenoid sinus and sella turcica]. *Boll Soc Ital Biol Sper.* 1983;59(4):413-7.

Received in 22/6/2009

Accepted in 7/8/2009