Rev Bras Clin Med. São Paulo, 2012 nov-dez;10(6):547-9

CASE REPORT

Echocardiographic diagnosis of acute aortic dissection in the emergency room. Case report*

Diagnóstico ecocardiográfico da dissecção aórtica aguda na sala de emergência. Relato de caso

Mauro de Deus Passos[1], Luciano Moreira Alves[2], Gustavo Carvalho[3]

*Received from Clinicare Multiclínica. Formosa, GO.

SUMMARY

BACKGROUND AND OBJECTIVES: The transthoracic echocardiography in the emergency room, by ultra-portable equipment has been increasingly useful for the diagnosis of acute dissection of ascending aorta, reason for the present report, the objective of which was to elucidate this emergency, using that important propedeutic method.
CASE REPORT: A previously healthy, 49 year-old patient admitted to the Emergency Unit with typical chest pain (without triggers) whose diagnosis of acute aortic dissection was performed with the aid of transthoracic echocardiography.
CONCLUSION: Considering that 65% of intimal tears occur in the ascending aorta, transthoracic echocardiography is a fast and effective tool in a medical emergency. The method has a sensitivity of 59%–85% and specificity of 63%–96% for the diagnosis of aortic dissection. It is noteworthy that, even though infrequent in experienced hands, negative findings at transthoracic echocariography do not rule out the diagnosis of this disease.

Keywords: Acute aortic dissection, Chest pain, Transthoracic echocardiography.

RESUMO

JUSTIFICATIVA E OBJETIVOS: A ecocardiografia transtorácica na sala de emergência, por meio de equipamentos ultraportáteis, tem sido cada vez útil no diagnóstico da dissecção aguda da aorta ascendente, o que justifica o presente relato, cujo objetivo foi elucidar o quadro emergencial com o auxílio desta importante ferramenta propedêutica.
RELATO DO CASO: Paciente de 49 anos, previamente saudável, admitido na Unidade de Emergência com quadro de dor torácica típica (sem fatores desencadeantes) cujo diagnóstico de dissecção aórtica aguda foi realizado com o auxílio do ecocardiograma transtorácico.
CONCLUSÃO: Considerando-se que 65% das lacerações intimais ocorrem na aorta ascendente, o ecocardiograma transtorácico é uma ferramenta rápida e eficaz em uma situação de emergência médica. O método apresenta sensibilidade de 59 a 85% e especificidade de 63% a 96% para o diagnóstico de dissecção aórtica. Ressalta-se que, mesmo infrequentes em mãos experientes, achados negativos ao ecocardiograma transtorácico não descartam o diagnóstico desta comorbidade.

Descritores: Dissecção aórtica aguda, Dor torácica, Ecocardiograma transtorácico.

INTRODUCTION

Acute aortic dissection is characterized by rapid separation of the medial layer, with infiltration of blood into this new space created between the intima and adventitia, creating a false lumen, with hematoma formation[1]. It is a rare condition, affecting 2.5 to 3.5 / 100,000 individuals[2], with clear predominance in males (5:1)[2]. However, it has a high mortality rate – 75% in the first 48h and 90% in the first week[3]. It is most common in the elderly, typically occurring between individuals of the age group between 60 and 70 years[4]. Hypertension is the most common predisposing factor, found in 78% of cases[5]. Its diagnosis is mainly based on clinical history (excruciating pain radiating to the back, interscapular region) and physical examination (asymmetry of pulses, and the aortic diastolic murmur) and its main differential diagnosis is acute coronary syndromes. Many patients may have, together, an acute coronary event. Coronary ischemia associated with aortic dissection is relatively rare, but when present, may have a fatal outcome for the patient. The diagnosis of acute corona-

1. Specialist in Internal Medicine by SBCM; Qualification in Emergency Medicine by SBCM. Specialist in Cardiology by SBC. Attending Physician at "Tribunal Regional do Trabalho da 10ª Região", Brasília-DF. Attending Physician (Cardiology, echocardiography and vascular ultrasound) at "Clinicare Multiclínica". Formosa, GO, Brazil
2. Specialist in Radiology and Diagnostic Imaging (CBR/AMB). Radiology Department at "Hospital São Francisco de Assis", Goiânia, GO, Brasil. Emergency Service at "(HUAPA) Hospital de Urgências de Aparecida de Goiânia", Aparecida de Goiânia, GO, Brazil
3. Specialist in Cardiology by SBC. Qualification in Hemodynamics and Interventional Cardiology. Master of Health Sciences by Universidade Federal de Goiás (UFG). Attending Physician (Cardiologist / Hemodynamicist) at "Hospital Universitário da UFG". Goiânia, GO, Brazil

Presented in January, 12, 2012
Accepted in July, 31, 2012

Adress from correspondence:
Mauro de Deus Passos, M.D.
Clinicare Multiclínica
Avenida Lagoa Feia, 12 - Centro
73801-320 Formosa, GO.
E-mail: mauropasssos@cardiol.br

ry syndrome instead of aortic dissection can lead to inappropriate administration of thrombolytic agents, anticoagulants or glycoprotein IIb/IIIa inhibitors, resulting in catastrophic consequences[6]. Spittell et al (1993) studied 236 cases of aortic dissection and observed that the dissection affects the right coronary artery more frequently than the left[5].

CASE REPORT

A 49-year patient attended at the Emergency Department complaining of chest pain that began abruptly, radiating to the back, without precipitating factors, associated with pale skin and profuse sweating. He had no history of smoking, alcoholism and obesity and was a regular physical activity practitioner. No family history of heart disease. On physical examination, he was hypotensive (blood pressure 70/40 mmHg), with signs of peripheral hypoperfusion and a grade I/VI diastolic murmur in the aortic area. The pulses were thready and symmetrical. Electrocardiogram and markers of myocardial necrosis series were performed, all normal. The TTE (Figure 1) at the bedside with portable equipment (GE Vivid "E" - General Electric) with all the technical difficulties, showed dissection of the ascending aorta (intimal flapping), associated with aortic insufficiency.

Computed angiotomography (Angio-CT) of the chest (Figure 2) revealed the dissection *flap* arising from the ascending thoracic aorta (Stanford type A) and extending into its descending segment. The patient was immediately sent to Cardiac Surgery, which proved the Stanford type A dissection associated to major aortic regurgitation, in which the treatment was made by the replacement of the native valve by mechanical prosthesis. The reconstruction of the aortic root with organic graft was also carried out. Postoperatively, the patient evolved with clinical stabilization. Histopathological examination of the aortic valve showed myxoid degeneration.

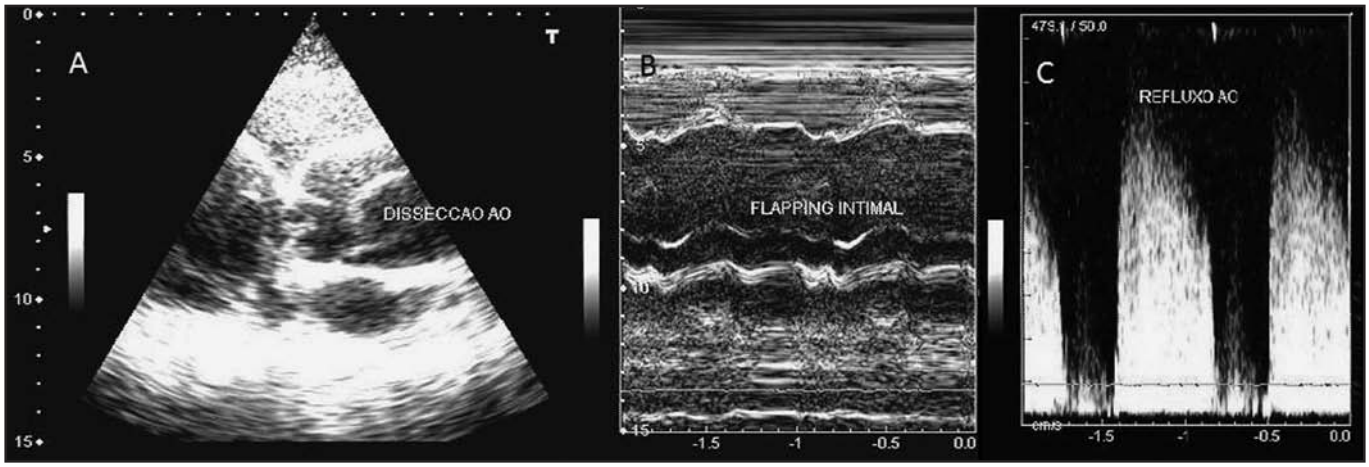

Figure 1 – Transthoracic echocardiography.

A) Longitudinal parasternal view: aortic dissection with destruction of the valve apparatus, B) Mode "M" of the aortic valve: intimal flapping, C) Spectral Doppler of the left ventricle outflow tract: aortic reflux.

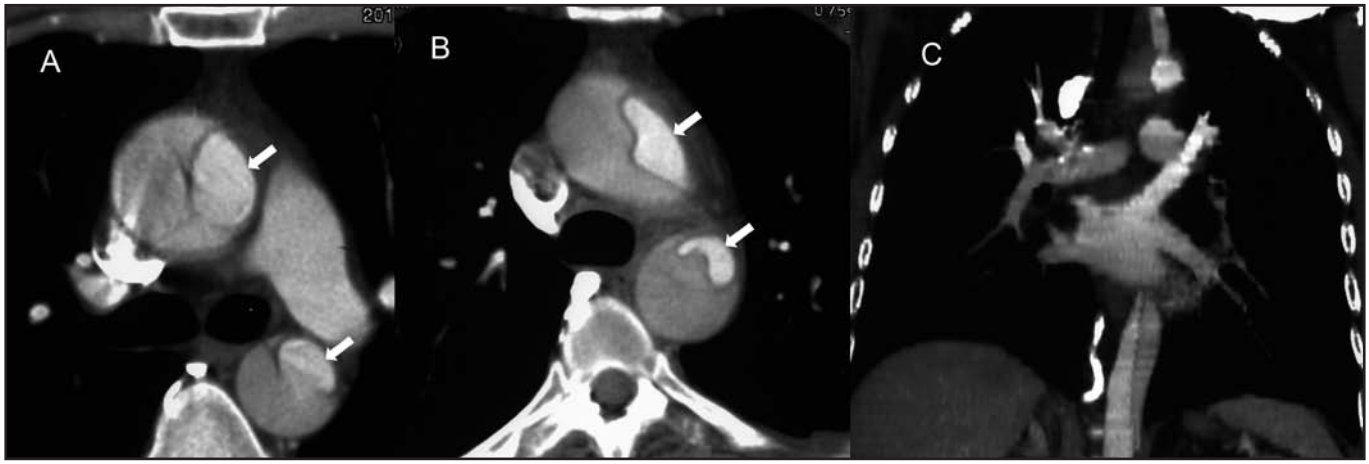

Figure 2 – Thoracic Angio-CT.

A) axial image through the thorax demonstrating that the intimal *flap* arises from ascending aorta, proximal to the left subclavian artery (Stanford type A dissection), resulting in two lumina: a false lumen and a true lumen – the latter identified by the white arrows. B) axial image showing the dissection flap in the aortic arch. C) Coronal reformatted images show intimal flap involvement of the descending thoracic aorta.

DISCUSSION

The two commonest classification systems include the DeBakey and Stanford classifications. The Stanford classification divides aortic dissections into type A and type B. In type A the dissection affects the ascending aorta, and eventually progresses to the distal aorta. The type B dissection begins at the level of the descending aorta, after the emergence of the left subclavian artery[7]. The DeBakey classification distinguishes types I, II and III. Type I involves both the ascending and the descending aorta; the type II affects only the ascending aorta (including the aortic arch) and type III spares the ascending aorta and aortic arch.

Computed tomography (CT) scan of the chest has been the gold standard method for diagnosis and monitoring of patients with aortic disease[8], including helical CT and multisection CT, due to the shorter acquisition time, wide availability, and high diagnostic accuracy[9]. Magnetic ressonance has high accuracy, sensitivity and specificity equal to or superior to CT. Angiography of the aorta is an examination into disuse and was the most important until the advent of noninvasive tests[8]. Transthoracic echocardiography (TTE) is a noninvasive examination that can detect the increase in diameter of the aorta (which can be adjusted for age and body mass) and association with diseases that can infer the possible presence of aortic aneurysmal disease, such as valve bicuspid aortic valve[8] and may help detect an ascending aortic dissection flap[9]. The TTE has a reported sensitivity of 59%-85% and a specificity of 63%-96% for the diagnosis of aortic dissection[10]. The advent of portable echocardiography and ultraportable equipments have become practical, useful and promising tools in the hands of cardiologists and of attending physicians at emergency, radiology and intensive care units. Immersion courses, such as ECOTIN (Course of Ultrasound in Critical Care) sanctioned by the Association of Intensive Medicine (AMIB), offer an almost entirely devoted to the use of echocardiography in intensive care units (ICU) program.

The treatment of aortic dissection may be clinical (especially with the use of beta-blockers, in order to reduce the shear stress exerted by blood against the vessel wall), conventional surgery (remodeling of the valve and the aortic root, aortic valve replacement and tubular grafts) or percutaneous endovascular (use of stents).

The use of TTE, especially considering the advent of ultraportable equipment in the emergency room as the initial diagnostic imaging technique was a somewhat atypical approach to the diagnosis of aortic dissection. This modality has greater sensitivity and specificity for the diagnosis of Stanford type A aortic dissection[4]. Turhan et al (2004)[11] and Bilku, Steadman and Jordan[12] reported the diagnosis of Stanford type B aortic dissection by TTE. Some important findings that highlight the importance of TTE in the diagnosis of aortic dissection is that 65% of intimal tears occur in the ascending aorta, 20% in descending aorta, 10% in the aortic arch and 5% in abdominal aorta[10].

In summary, concerning the differential diagnosis of chest pain and considering the cost factor versus benefits, the realization of TTE is a fast and effective tool in a medical emergency. The goal during this screening test is not to depict echocardiographic details, but to diagnose conditions such as aortic dissection, pericardial effusion with or without cardiac tamponade, rupture of the left ventricle and other potentially fatal conditions. The lack of visualization of aortic dissection in the TTE does not rule out the diagnosis of aortic dissection. In acute coronary syndromes, the presence of akinetic or dyskinetic areas can be the first sign of myocardial infarction. However, the distinction between dyskinetic areas and normal areas (or its distinction with old events, as a previous myocardial infarction) is an attribute of a specialist in cardiology with great experience in echocardiography and would require a long learning curve by the emergency physician. The role of TTE in an emergency room would be equivalent to the ultrasound method applied in case of trauma, known as FAST (Focused Assessment with Sonography for Trauma), focused in diagnosing potentially fatal lesions.

REFERENCES

1. Mészáros I, Mórocz J, Szlávi J, et al. Epidemiology and clinicopathology of aortic dissection. Chest. 2000;117(5):1271-8.
2. Khandheria BK, Tajik AJ, Taylor CL, et al. Aortic dissection: review of value and limitations of two-dimensional echocardiography in a six-year experience. J Am Soc Echocardiogr. 1989;2(1):17-24.
3. Khan IA, Nair CK. Clinical, diagnostic, and management perspectives of aortic dissection. Chest. 2002;122(1):311-28.
4. Brunson JM, Fine RL, Schussler JM. Acute ascending aortic dissection diagnosed with transthoracic echocardiography. J Am Soc Echocardiogr. 2009;22(9):1086.e5-7.
5. Spittell PC, Spittell JA Jr, Joyce JW, et al. Clinical features and differential diagnosis of aortic dissection: experience with 236 cases (1980 through 1990). Mayo Clin Proc. 1993;68(7):642-51.
6. Lentini S, Perrotta S. Aortic dissection with concomitant acute myocardial infarction: From diagnosis to management. J Emerg Trauma Shock. 2011;4(2):273-8.
7. Daily PO, Trueblood HW, Stinson EB, et al. Management of acute aortic dissections. Ann Thorac Surg. 1970;10(3)237-47.
8. Almeida RMS, Saadi EK, Fonseca JHA, et al. Doenças da aorta. In: Paola AV, Barbosa MM, Guimarães JI, (editores). Livro-texto da Sociedade Brasileira de Cardiologia. Editora Manole; 2012. p. 1320-38.
9. McMahon MA, Squirrell CA. Multidetector CT of aortic dissection: a pictorial review. Radiographics. 2010;30(2):445-60.
10. Isselbacher EM. Doenças da aorta. In: Libby P, et al (editores). Tradado de Medicina Cardiovascular. Elsevier; 2010. p. 1457-89.
11. Turhan H, Topaloglu S, Cagli K, et al. Traumatic type B aortic dissection causing near total occlusion of aortic lumen and diagnosed by transthoracic echocardiography: A case report. J Am Soc Echocardiogr. 2004;17(1)80-2.
12. Bilku RS, Steadman CD, Jordan PJ. Acute DeBakey Type III (or Stanford Type B) aortic dissection diagnosed by transthoracic echocardiography. J Am Soc Echocardiogr. 2008;21(9)1080.