

CASE REPORT

Gastric ulcer perforation credited to paracoccidioidomycosis. Case report with autopsy

Úlcera gástrica perfurada por paracoccidioidomicose. Relato de caso com necrópsia

Short title: Gastric ulcer perforation credited to paracoccidioidomycosis

Mariana Bellaguarda de Castro Sepulveda¹, Rafael Fantelli Stelini², Pompeu Tomé Ribeiro de Campos¹, Carlos Osvaldo Teixeira¹, Maria Aparecida Barone Teixeira²

Study carried out at Grupo de Estudo em Correlação Anatomoclínica of Hospital e Maternidade Celso Pierro of Faculdade de Medicina of the Pontifícia Universidade Católica de Campinas, Campinas, SP, Brazil.

1. Faculdade de Medicina, Pontifícia Universidade Católica de Campinas, Campinas, SP, Brazil.

2. Laboratório de Anatomia Patológica do Hospital e Maternidade Celso Pierro Pontifícia Universidade Católica de Campinas, Campinas, SP, Brazil.

Received on: May 21, 2013 – Accepted on: Sep 13, 2013

Conflict of interest: none.

Corresponding author: Mariana Bellaguarda de Castro Sepulveda – Rua Espírito Santo, 1.136 – Cerâmica – Zip Code: 09530-701 – São Caetano do Sul, SP, Brazil – Phone.: 55 (19) 9341-5399 - E-mail: mbellaguardasepulveda@yahoo.com.br

ABSTRACT

Paracoccidioidomycosis or South American blastomycosis is an endemic disease that occurs predominantly in rural South America, caused by a thermo-dimorphic fungus named *Paracoccidioides brasiliensis*. Its epidemiologic importance relates to its characteristics of transmissibility, susceptibility and morbidity, in addition to its high cost due to prolonged medical monitoring. It has a polymorfism in the description, explained by absent or nonspecific initial symptoms such as night sweats, weight loss or fever, and later symptoms according to its location of involvement. The objective of this study was to report a case of uncommon presentation of this pathology. The case report is the autopsy of a 74-year-old, white, female patient with predominant manifestation in the gastrointestinal tract originating from paracoccidioidomycosis, and complicated by one of the gastric ulcers perforation. This is an unusual presentation, and reports of gastric ulcer perforation credited to this agent were not found in the literature.

Keywords: Autopsy; Paracoccidioidomycosis; Stomach ulcer; Peptic ulcer; Peptic ulcer perforation; Case reports

RESUMO

Paracoccidioidomicose ou blastomicose Sul Americana é uma enfermidade endêmica rural que ocorre predominantemente na América Latina, tendo como etiologia o fungo termodimórfico *Paracoccidioides brasiliensis*. Sua importância epidemiológica está nas características de transmissibilidade, suscetibilidade e morbidade dos casos, além de seu alto custo, devido ao acompanhamento médico prolongado. É uma doença cujos sintomas iniciais são ausentes ou inespecíficos como sudorese noturna, emagrecimento ou febre, diferente dos sintomas tardios, que acontecem conforme sua localização de acometimento, o

que justifica o polimorfismo em sua descrição. O objetivo deste estudo foi relatar um caso de apresentação incomum dessa doença. Caso clínico com necrópsia de paciente do gênero feminino, 74 anos, branca, com manifestações clínicas predominantes no trato gastrintestinal provenientes de paracoccidioidomicose complicada pela perfuração de uma das úlceras gástricas. Trata-se de uma apresentação incomum e não foram encontrados relatos na literatura de perfuração de úlcera gástrica creditada a esse agente.

Descritores: Autópsia; Paracoccidioidomicose; Úlcera gástrica; Úlcera péptica perfurada; Relatos de casos

INTRODUCTION

Paracoccidioidomycosis or South American blastomycosis is caused by the thermally dimorphic fungus *Paracoccidioides brasiliensis*, usually after being inhaled in an esporulated form⁽¹⁻⁴⁾, being swallowed after contact with contaminated object or food^(3,5), or rarely by inoculation thru transcutaneous trauma^(2,4).

It affects Latin America, however, most recently won global importance due to the higher possibility of transmission: settlements, fast shipping, and increasing numbers of immunocompromised (mainly due to the acquired immunodeficiency syndrome – (Aids) who are more susceptible to infections and reactivations. Accordingly, there is an increasing number of reported cases of this disease in other locations than those expected⁽⁵⁻⁸⁾, and today, in Brazil, it represents the highest mortality rate among the systemic mycoses, with the value of 1.45 cases inhabitants per million^(4,7).

It mainly affects the age group from third to fifty decades with a ratio male: female adult 15:1^(3,4,9), since estrogen confers protection to women^(1,3,10). The main risk factor for infection

by the fungus is the management of soil and contaminated objects, as well as alcoholism, smoking and low immunity situations^(1,3,4,7,9).

After infection, the patients are asymptomatic or have nonspecific symptoms such as night sweats, weight loss and fever. However, with the evolution of the disease, the patient begin to show signs and symptoms of possible specific sites affected^(2,4,11), explaining the polymorphism of the disease. The main organs affected are the lungs and oral cavity, thus, the patient experiences the symptoms of pulmonary infection, followed by painful oral ulcer feature that does not improve spontaneously. However, there is also the possibility that the patient remain asymptomatic⁽⁴⁾.

Paracoccidioidomycosis was classified into three clinical forms: the regressive form, characterized as a benign disease with mild symptoms and spontaneous regression even without treatment. The progressive form, which shows progress in clinical; and the latent form characterized by clinical manifestations caused by scarring. The progressive form shows a subdivision based on the evolution period and may be acute or subacute (juvenile type), or chronic (adult type). The first one is characterized by the evolution of the primary complex for systemic disease with predominant involvement of the mononuclear phagocyte system. The second presents reactivation of latent focus even years after its formation, with predominant pulmonary involvement. Regarding severity, acute form can be mild or severe and chronic form can be mild, moderate or severe^(11,12).

The primary involvement usually occurs in the lungs, from where it is drained to hilar lymph nodes forming a primary complex similar to the tuberculosis⁽¹³⁾. The disease may regress, resulting in the healing process or latent focus (with viable micro-organisms), or move up spreading for the organism thru blood and/or lymphatic circulation^(2-4,12). Once present in abdominal lymph nodes, it gains the potential to spread thru the lymphatic retrograde circulation until gastrointestinal tract, and may thus reach stomach^(3,5,12,14,15).

Involvement of the gastrointestinal tract is increasingly seen in exams as radiological or endoscopic, or necropsies, which has an incidence of 2.7 to 28.4%⁽¹³⁾ presenting ileocecal as the most affected^(3,5,12,16). However, it is uncommon, even in patients with Aids or immunocompetent, especially in the proximal gastrointestinal tract portion^(5,12,17,18). The stomach involvement may be presented as infiltrative, vegetating, ulcerate⁽⁹⁾ and/or erosive lesion⁽⁸⁾.

CASE REPORT

Female patient, 74 years old, white, from Botelho, Minas Gerais, Brazil, ex-smokers and ex-alcoholic, was accompanied in Hospital e Maternidade Celso Pierro (HMCP) of Pontifícia Universidade Católica de Campinas (PUC-Campinas) 4 years ago by rheumatic heart disease, chronic diarrhea and macrocytic anemia. She presented epigastric pain episodes, having been submitted to an esophagogastroduodenoscopy about 2 months before death. The exam demonstrated erosive gastritis in the antrum, no ulcers, and urease test for *Helicobacter pylori* positive. Biopsy was not performed, but the patient showed clinical improvement after specific treatment.

In the last ambulatory visit, a month before death, she presented, at oroscopy and rhinoscopy, shallow ulcers well defined, clean background, with raised edges and no redness around, measuring 2.5cm 1.0cm in diameter, localized in the nose, lip and palate, accompanied by cervical lymphadenopathy, being requested the dermatology review and histological examination. Before performing these procedures, the patient developed worsening abdominal pain accompanied by bloating, poor general condition and acute respiratory failure, going into septic shock and death. It was hypothesized and suggested a research for Aids or other immunosuppressive disease, but there was no time for its accomplishment.

The autopsy revealed pre-pyloric ulcer perforated, whose histology showed granulomatous inflammation with the presence of *P. brasiliensis*. (Figures 1-4).

Almost all organs examined had lesions and/or yeast form fungal structures: skin, liver, spleen, pancreas, intestines, adrenals, kidneys, gall bladder and lymph nodes, except for the lungs and thyroid, where fungus was not found in several fragments analyzed.

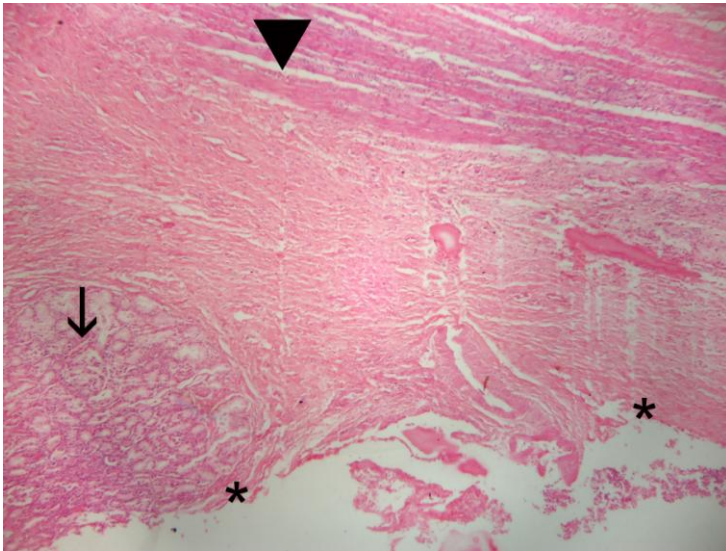


Figure 1. Region demonstrating pre-pyloric ulcer (*), with no mucosal changes (→), thickening of submucosa and longitudinal muscle layer preserved (↔). Hematoxylin and eosin, original magnification 40x

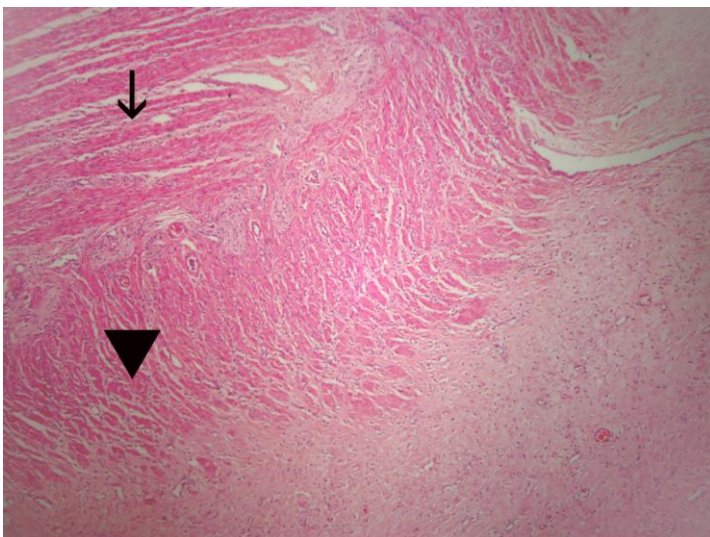


Figure 2. Demonstrating longitudinal muscles (→), transverse muscles (*), and thickening of serosa. Hematoxylin and eosin, original magnification 40x

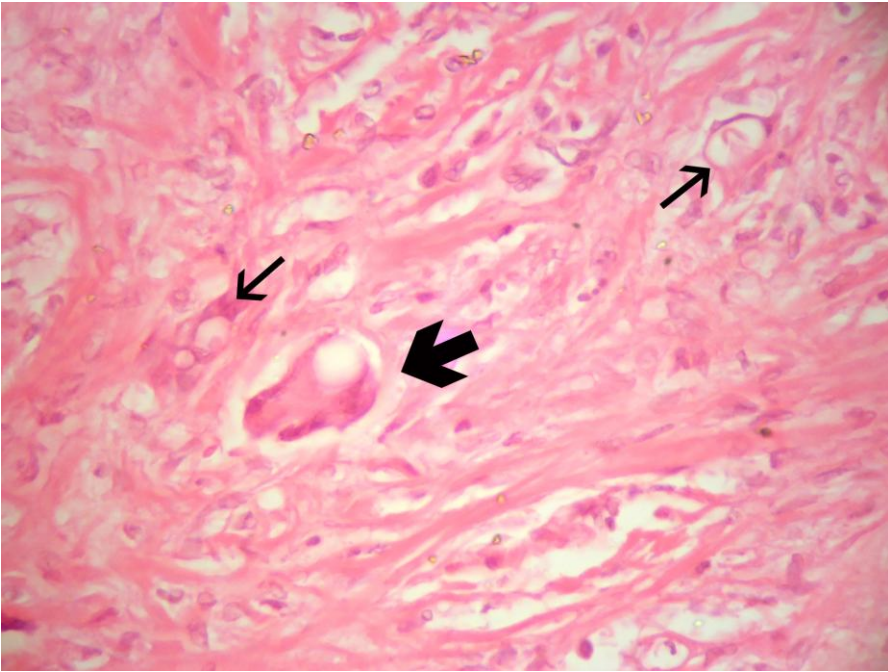


Figure 3. Demonstrating gigantocytes phagocytosing fungus (→), and other fungi isolated (→) Hematoxylin and eosin, original magnification 400x

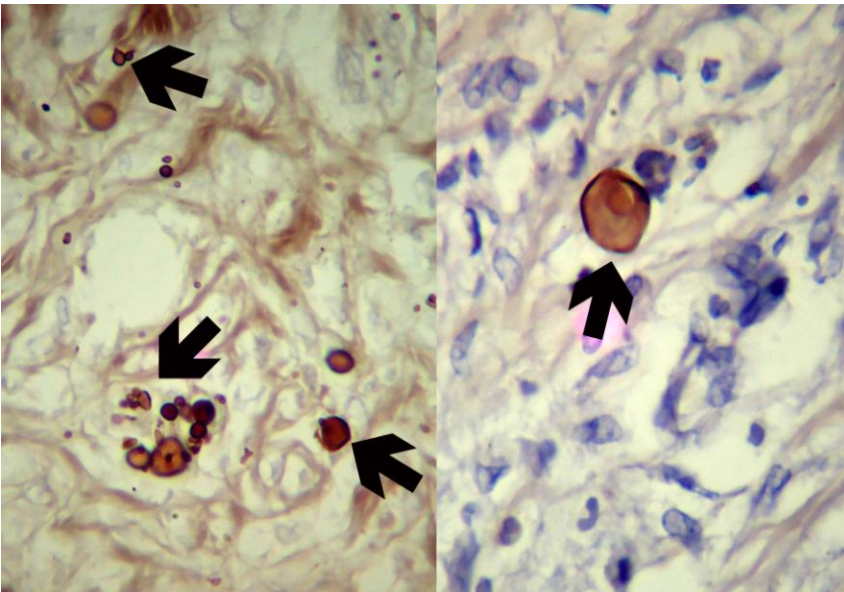


Figure 4. Demonstrating *Paracoccidioides brasiliensis* (→). Grocott, original magnification 400x.

DISCUSSION

This case can be considered as a severe form of paracoccidioidomycosis due to overall poor health and nutritional status of the patient, the type of lymph node tumor (>2.0cm) and the cutaneous and clinical involvement of other organs⁽¹¹⁾, including stomach, in the form of an ulcer. This is a rare case of gastric ulcer with perforation related to *P. brasiliensis*, with histological confirmation of the lesion and systemic contamination of the organs mentioned.

Regarding the type of involvement, this case should probably be chronic because of the possible relationship between episodes of diarrhea and anemia macrocytic, both long-standing involvement of the gastrointestinal tract and its lymphatic noted at autopsy, the history of alcoholism and the patient age. Nevertheless, the possibility of the acute form on it cannot be excluded, which, in this case, would be characterized by the involvement of the mononuclear phagocyte system and gastrointestinal tract, as well as the absence of pulmonary lesions^(11,14).

The fact of not having pulmonary involvement is unusual in the chronic form⁽¹¹⁾ but does not exclude, absolutely, the possibility of pulmonary involvement discreet, not evidenced by research methods both pre and post-mortem. During a clinical study conducted at the Universidade Federal de Mato Grosso do Sul, of 270 patients with pulmonary lesions credited to the fungus, 60 of them had respiratory symptoms. This feature of the clinical presentation may be explained by the location predominantly interstitial lesions⁽⁹⁾.

Because the patient did not show clinical signs suggestive of pulmonary paracoccidioidomycosis, plus her age outside the range of the highest incidence of this disease and the absence of other findings, there was a devaluation of this diagnosis at first, which would have been paramount to the favorable resolution of the case, until the patient

presents with oral and nasal mucosa ulcer, cervical lymph node, and on this occasion follows rapidly to death after gastric ulcer perforation and subsequent peritonitis. It is noteworthy that in this case, although this disease occurs predominantly in men, the fact that the patient was a woman not alienate the diagnosis, since she was an post-menopausal woman with estrogen levels decreased. Furthermore, although the HIV serology has not been performed, it should be understood that cannot be infer a virus contamination based on the severity presentation, since gastrointestinal involvement is rare also in HIV positive patients and, when manifested, appears in acute form⁽¹⁸⁾.

Gastric involvement may be due to hematogenous spread directly and/or reflux of lymph from abdominal lymph nodes previously infected thru blood and/or lymphatic^(2,3,14,15). Other possibilities, less accepted, are by swallowing continuous secretions from the upper digestive tract and/or respiratory contaminated with microorganisms, or for retrograde flow of digestive secretions, since the patient had longstanding intestinal complaints^(2,3,5).

In cases in the literature about gastric involvement by *P. brasiliensis*, there was anatomical and functional changes of the stomach itself. The influence of these factors to the spread of the fungus is unknown, but as in the cases reviewed, the patient presented ulcer after a functional alteration of the organ from the specific treatment for gastritis, which would reduce the concentration of hydrogen ions in the stomach⁽⁵⁾.

CONCLUSION

In this report, the post-mortem examination revealed one of the probable causes of the abdominal pain: a gastric ulcer, that was not visualized at esophagogastroduodenoscopy performed 2 months prior to death, with chronic inflammation containing yeast. However, we cannot conclude whether the patient developed a peptic ulcer that, in a second moment, was

contaminated by yeasts leading to local inflammatory process described above, or it was primarily the presence of yeasts triggering such injury or, if they occurred simultaneously.

Furthermore, the autopsy allowed the realization of a loosely described involvement in paracoccidioidomycosis, which is the stomach, in a presentation even more unusual as it evolved with ulcer perforation. This fact, as well as helping demonstrate the great variability of presentation of this disease, also calls attention to the possibility of this diagnosis in similar cases.

REFERENCES

1. Martinez R. Blastomicose Sul-Americana – Etioepidemiologia e ecologia. In: Veronesi R. & Focaccia R, editores. Tratado de infectologia. Atheneu: São Paulo; 2004. p. 1101-3.
2. Ferreira MS. Blastomicose Sul-Americana – imunopatogênese e patologia. In: Veronesi R, Focaccia R, editores. Tratado de infectologia. Atheneu: São Paulo; 2004. p.1103-7.
3. Bravo EA, Zegarra AJ, Piscocoya A, Pinto JL, de Los Rios RE, Prochazka RA, et al. Chronic diarrhea and pancolitis caused by paracoccidioidomycosis: a case report. *Case Rep Med.* 2010;30(4). doi:10.1155/2010/140505
4. Shikanai-Yasuda MA, Telles Filho Fde Q, Mendes RP, Colombo AL, Moretti ML. [Guidelines in paracoccidioidomycosis]. *Rev Soc Bras Med Trop.* 2006;39(3):297-310. Portuguese.
5. Gabellini Gde C, Martinez R, Ejima FH, Saldanha JC, Módena JL, Velludo MA, et al. [Gastric paracoccidioidomycosis. A case report and considerations on the pathogenesis of this disease]. *Arq Gastroenterol.* 1992;29(4):147-52. Portuguese.
6. Kamei K, Sano A, Kikuchi K, Makimura K, Niimi M, Suzuki K, et al. The trend of imported mycoses in Japan. *J Infect Chemother.* 2003;9(1):16-20.

7. Martinez R, Meneghelli UG, Dantas RO, Fiorillo AM. [Gastrointestinal involvement in South American blastomycosis (paracoccidioidomycosis). I. Clinical, radiological and histopathological study]. *AMB Rev Assoc Med Bras*. 1979;25(1):31-4. Portuguese.
8. Onda H, Komine M, Murata S, Ohtsuki M. Letter: Imported paracoccidioidomycosis in Japan. *Dermatol Online J*. 2011;17(12):11.
9. Paniago AM, Aguiar JI, Aguiar ES, da Cunha RV, Pereira GR, Londero AT, et al. [Paracoccidioidomycosis: a clinical and epidemiological study of 422 cases observed in Mato Grosso do Sul]. *Rev Soc Bras Med Trop*. 2003;36(4):455-9. Portuguese.
10. Salazar ME, Restrepo A, Stevens DA. Inhibition by estrogens of conidium-to-yeast conversion in the fungus *Paracoccidioides brasiliensis*. *Infect Immun*. 1988;56(3):711-3.
11. Mendes RP. Blastomicose Sul-Americana – quadro clínico. In: Veronesi R, Focaccia R, editores. *Tratado de infectologia*. Atheneu: São Paulo; 2004. p. 1107-18.
12. Martinez R, Módena JL, Barbieri-Neto J, Fiorillo AM. [Endoscopic evaluation of the involvement of the esophagus, stomach and duodenum in human paracoccidioidomycosis]. *Arq Gastroenterol*. 1986;23(1):21-5. Portuguese.
13. Severo LC, Geyer GR, Londero AT, Porto NS, Rizzon CF. The primary pulmonary lymph node complex in paracoccidioidomycosis. *Mycopathologia*. 1979;67(2):115-8.
14. Brunaldi MO, Rezende RE, Zucoloto S, Garcia SB, Módena JL, Machado AA. Co-infection with paracoccidioidomycosis and human immunodeficiency virus: report of a case with esophageal involvement. *Am J Trop Med Hyg*. 2010;82(6):1099-101.
15. Fonseca LC, Mignone C. Paracoccidioidomycosis of the small intestine. Radiologic and anatomical aspects of 125 cases. *Rev Hosp Clin Fac Med Sao Paulo*. 1976;31(3):199-207.

16. Mendes RP. Blastomicose Sul-Americana – diagnóstico laboratorial e radiológico. In: Veronesi R, Focaccia R, editores. Tratado de infectologia. Atheneu: São Paulo; 2004. p. 1118-24.
17. Martinez R, Rossi MA. Duodenal paracoccidioidomycosis with digestive bleeding. Rev Inst Med Trop Sao Paulo. 1984;26(3):160-4.
18. Goldani LZ. Gastrointestinal paracoccidioidomycosis: an overview. J Clin Gastroenterol. 2011;45(2):87-91.

|

