

## Relapsing *Klebsiella pneumoniae* liver abscesses in a non-asian diabetic man

### *Abcessos hepáticos recidivantes provocados por Klebsiella pneumoniae num homem diabético não asiático*

Zélia Neves, Úrsula Segura, André Valente, Maria Helena Pacheco, José Malhado

Recebido do Hospital Curry Cabral.

#### ABSTRACT

The *Klebsiella pneumoniae* invasive syndrome, first described in Asia, is being reported in other parts of the world. It causes liver abscesses, with or without extrahepatic lesions. Diabetes mellitus is the most common hosts' underlying condition. It's frequent among asian people, even outside Asia, appearing to exist genetic factors, not yet established, increasing the risk. We present a case of a 55-year-old portuguese white diabetic man, who had a previous hospital admission due to *Klebsiella pneumoniae* pneumonia and a two-week latter diagnosis of liver abscess. 4 years latter he was readmitted with nausea, chills, fever and myalgias. He had elevated inflammatory markers and the CT-scan showed 2 liver abscesses. *Klebsiella pneumoniae* was isolated in blood and antibiotics were given with complete clinical and imaging resolution. We present this case of relapsing *Klebsiella pneumoniae* liver abscesses in a non-asian man emphasizing the growing incidence of this condition in Europe.

**Keywords:** Liver abscess; *Klebsiella pneumoniae*; *Klebsiella pneumoniae* invasive syndrome

#### RESUMO

O síndrome invasivo provocado por *Klebsiella pneumoniae*, descrito pela primeira vez na Ásia, tem vindo a ser reportado em outras partes do mundo. Provoca abcessos hepáticos, com ou sem lesões extra-hepáticas associadas. A diabetes mellitus é a condição predisponente do hospedeiro mais comum. É frequente nos indivíduos asiáticos, mesmo fora da Ásia, parecendo existir factores genéticos, ainda não estabelecidos, que aumentam o risco da infecção. Apresentamos o caso de um homem português de 55 anos, diabético que tinha uma admissão prévia no

hospital por pneumonia provocada por *Klebsiella pneumoniae*, com diagnóstico de abcesso hepático 2 semanas depois. 4 anos mais tarde, foi readmitido com um quadro clínico de náuseas, calafrios, febre e mialgias. Apresentava parâmetros inflamatórios elevados e a tomografia computadorizada (TC) abdominal revelou 2 abcessos. Foi isolada *Klebsiella pneumoniae* em hemoculturas e foram administrados antibióticos com completa resolução clínica e imagiológica. Apresentamos este caso de abcessos hepáticos recidivantes por *Klebsiella pneumoniae* num homem não asiático, enfatizando a incidência crescente desta entidade na Europa.

**Descritores:** *Klebsiella pneumoniae*; Abcessos hepáticos; Diabéticos; Relatos de casos

#### INTRODUCTION

*Klebsiella pneumoniae* is a Gram negative bacilli that usually causes respiratory and urinary tract infections. Since the 1980's a new invasive syndrome associated with this agent has been described in Asia, causing liver abscess<sup>(1,2)</sup> with extrahepatic septic metastases, resulting from haematogenic dissemination<sup>(3,4,5)</sup> (endophthalmitis, meningitis, necrotizing fasciitis) which can be life-threatening.

The *K. pneumoniae* invasive syndrome was recently described outside Asia, namely in the United States of America (USA),<sup>(6,7)</sup> and in many countries in Europe<sup>(8-15)</sup>. Yet, there is a predominance of asian people involvement, even outside Asia. That remains unclear, but in 2002 a study suggested that some genotypic and phenotypic characteristics identified in microorganism from Asian countries are different from the bacteria identified outside Asia<sup>(16)</sup>. More recently, however, there are descriptions of *K. pneumoniae* liver abscess in non-asian patients<sup>(17)</sup>.

That syndrome is usually caused by two specific serotypes of *K. pneumoniae*: K1 and K2<sup>(17)</sup>, which have a hypermucoviscous phenotype conferring more virulent properties.

We describe a case of relapsing liver abscess on a non-asian diabetic man.

#### CASE PRESENTATION

We present a case of a 55-year-old portuguese white man with previous background of type 2 diabetes, with peripheral arterial disease and retinopathy, elevated blood pressure, obesity, dyslipidemia and obstructive sleep apnea syndrome. His

Hospital Curry Cabral, Centro Hospitalar de Lisboa Central Portugal.

Data de submissão: 04/12/2014 – Data de aceite: 09/02/2015

Conflito de interesses: não há.

#### Corresponding address:

Zélia Neves

Morada: Avenida dos Cravos Vermelhos, 12 – 4ºB

2720-141 – Amadora, Portugal

Tel.: 0031 963735229 – E-mail: zeliacr.neves@gmail.com

© Sociedade Brasileira de Clínica Médica

medication was Insuline Lispro, Furosemide, Spirinolactone, Pentoxiphylline, Rosuvastatine, Clopidogrel and Lansoprazole. His alcohol intake was 120mg per day and he is an ex-smoker; no other drug use, travelling history or animal contact was reported.

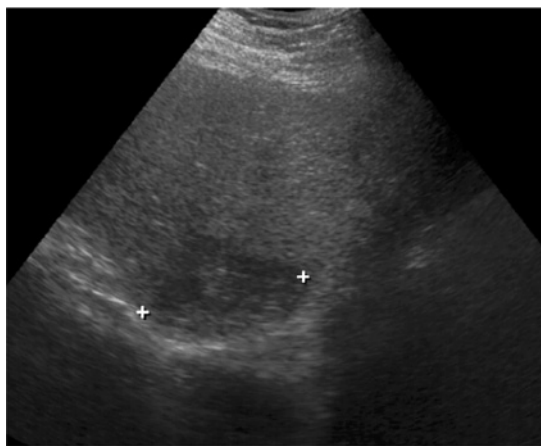
He was admitted on September 2009 with pneumonia, with *K.pneumoniae* isolation from blood cultures and sputum. He received antibiotic therapy for 10 days and was discharged. Two weeks latter he was readmitted with an hepatic abscess and he was submitted to surgical drainage. The same microorganism was isolated on cultures of aspirated pus and he received another course of antibiotics. A 4-month time abdominal CT-Scan was performed with complete resolution of the liver abscess.

On July 2013 the patient presented to the emergency department with a two-week history of nausea, chills, fever and myalgias. On physical exam he was vigil, oriented, blood pressure 135/78mmHg, heart rate 112bpm, febrile (38°C), pale, dehydrated, no enlarged lymph nodes, normal heart sounds and chest examinaton; his abdomen was distended, painfull, but no peritoneal reaction; the bowel sounds were normal; no hepatosplenomegaly or palpable masses. The physical exam was otherwise irrelevant.

Laboratory tests showed normocytic normochromic anemia (9,9g/dl), normal leucocyte count (9600/mL) with relative neutrophilia (81%), elevated liver enzymes (aspartate aminotransferase -129UI, alanine aminotransferase - 162UI, gamma glutamyl transferase - 416UI) and elevated inflammatory markers (C-Reactive Protein - 23.5mg/dl; Erythrocyte sedimentation rate 78mm/hr); his urea was slightly elevated, with a normal creatinine.

His urine analysis revealed an elevated leucocyte and erythrocyte count.

A chest radiography was performed and it was normal. The abdominal ultrasonography showed an heterogeneous hepatomegaly, with no focal lesions (Figure 1). The renal ultrasonography revealed enlarged kidneys without obstructive lesions.



**Figure 1.** Abdominal ultrasonography. The abdominal ultrasonography showed a heterogeneous hepatomegaly, with no focal lesions.

A urinary tract infection was assumed and ceftriaxone 2g ev id was started.

Besides antibiotic therapy, the patient maintained persistent fever and high inflammatory markers, and an abdominal CT-scan was ordered. Imaging findings were consistent with liver abscesses in IV and VIII segments (7 and 3.5 cm) (Figure 2).

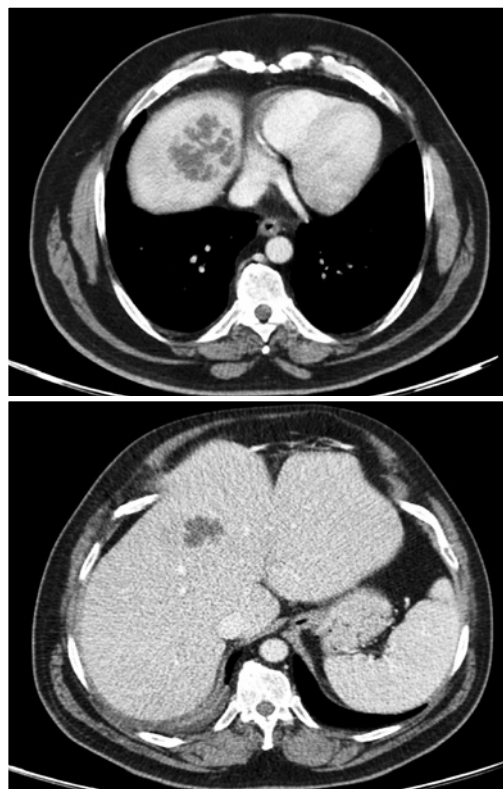
A *K. pneumoniae* was isolated from blood cultures and the urine culture was negative.

Due to the abscesses localization it was decided to have a conservative approach and parental Piperacillin-Tazobactam and Metronidazol was given. The patient was afebrile 3 days after, with progressive clinical improvement, and was discharged from the hospital at 19th day since admission. He completed a 4 week course of antibiotherapy. The follow up abdominal CT-scans showed improvment at two-month (Figure 3) time and a normal liver apperance on 6th month (Figure 4).

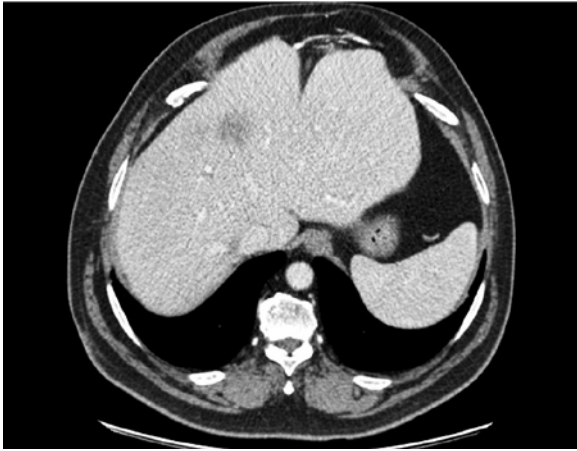
## DISCUSSION

*K.pneumoniae* invasive syndrome was recently described as an infection of the liver caused by a specific serotype of that microorganism. It can have extrahepatic complications and be very severe.

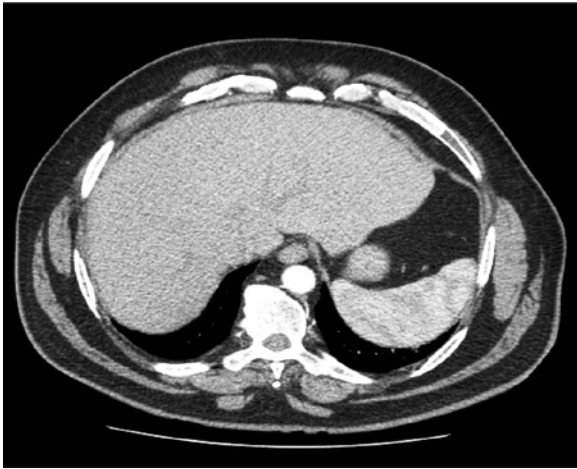
According to the definition of *K.pneumoniae* invasive syndrome proposed by L Kristopher et al in 2012,<sup>(16)</sup> the patient that we presented had a clinical probable invasive syndrome at the time of current admission in the hospital



**Figure 2.** Abdominal CT-Scan. The imaging were consistent with liver abscesses in IV and VIII segments (7 and 3.5cm).



**Figure 3.** Abdominal CT-Scan 2 months after treatment. CT-scan showed marked improvement in the abscesses.



**Figure 4.** CT-scan revealed complete resolution of the abscesses.

as he had a *K.pneumoniae* liver abscess as the sole presenting clinical manifestation. When the liver abscess have extrahepatic complications, especially central nervous system involvement, necrotising fasciitis or endophthalmitis, the syndrome is classified as definite. The same authors also proposed a microbiological definition of the syndrome: it is definite if there is an identification of the K1 or K2 serotypes and it is probable when there is a hypermucoviscous phenotype identified by the string test.

This syndrome was first described in southeast asian countries<sup>(1,2)</sup>, however there are 38 cases reported in the USA. 50% of the affected patients in USA are asian-descendents. The other half have an other ethnic origin<sup>(17)</sup>.

The most common underlying condition on patients affected by this disorder is diabetes mellitus and it seems to be an association between uncontrolled hyperglycemia and metastatic lesions<sup>(18,19)</sup>. It hasn't been identified specific human genes predisposing to the infection, but they seem to exist once the disease is more common in Asian people<sup>(19)</sup>. Our patient belongs

to the diabetic risk group and he had a poor glycemic control with macro and microvascular complications. Hypothetically, he may have a personal or genetic predisposition once he already had the same clinical presentation four years ago and, at the time, the liver abscess was resolved.

We present this case report because its rarity outside asian countries as well as the particularity of a relapse of the liver abscess in the same patient four years after the first episode.

## REFERENCES

1. Chang FY, Chou MY, Fan RL, Shiao MF. A clinical study of *Klebsiella* liver abscess. *Taiwan Yi Xue Hui Za Zhi* 1988;87:282-87.
2. Chang FY, Chou MY. Comparison of pyogenic liver abscesses caused by *Klebsiella pneumoniae* and non-*K pneumoniae* pathogens. *J Formos Med Assoc* 1995;94:232-37
3. Liu YC, Cheng DL, Lin CL. *Klebsiella pneumoniae* liver abscess associated with septic endophthalmitis. *Arch Intern Med* 1986; 146:1913-16.
4. Saccante M. *Klebsiella pneumoniae* liver abscess, endophthalmitis, and meningitis in a man with newly recognized diabetes mellitus. *Clin Infect Dis* 1999;29:1570-71.
5. Hu BS, Lau YJ, Shi ZY, Lin YH. Necrotizing fasciitis associated with *Klebsiella pneumoniae* liver abscess. *Clin Infect Dis* 1999; 29:1360-61.
6. Rahimian J, Wilson T, Oram V, Holzman RS. Pyogenic liver abscess: recent trends in etiology and mortality. *Clin Infect Dis* 2004; 39: 1654-59.
7. Pastagia M, Arumugam V. *Klebsiella pneumoniae* liver abscesses in a public hospital in Queens, New York. *Travel Med Infect Dis* 2008;6:228-33.
8. Moore R, O'Shea D., Geoghegan T., Mallon P, Sheehan G., Community-acquired *Klebsiella pneumoniae* liver abscess: an emerging infection in Ireland and Europe, *Infection*, 2013;41:681-686.
9. Garcia-Morillo JS, de la Cruz-Vicente F, Lopez-Ruiz T, Beranbeu-Wittel M, Hepatic abscess due to *Klebsiella pneumoniae* in an Asian immigrant. *Enferm Infecc Microbiol Clin*. 2006;24(9):585-6.
10. Gomez C, Broseta A, Otero JR, Chaves F, Primary pyogenic liver abscess caused by magA+ *Klebsiella pneumoniae* in Spain. *Clin Microbiol Newsl*.2007;29:100-2.
11. Karama EM, Willermain F, Janssens X, et al. Endogenous ophthalmitis complicating *Klebsiella pneumoniae* liver abscess in Europe:case report. *Int Ophthalmol*. 2008;28(2):111-3.
12. Sobirk SK, Struve C, Jacobsson SG. Primary *Klebsiella pneumoniae* liver abscess with metastatic spread to lung and eye, a North European case report of an emerging syndrome. *Open Microbiol J* 2010;4:5-7.
13. Decre D, Verdet C, Emirian A, et al. Emerging severe and fatal infections due to *Klebsiella pneumoniae* in two university hospitals in France. *J Clin Microbiol*. 2011;49(8):3012-4.
14. Moore L, Clarke L, Donaldson H, Azadian B, Community-acquired *Klebsiella pneumoniae* liver abscess: the London experience, *Infection* 2014;42:219-221.
15. Ko WC, Paterson DL, Sagnimeni AJ, et al. Community-acquired *Klebsiella pneumoniae* bacteremia: global differences in clinical patterns. *Emerg Infect Dis* 2002;8:160-66.
16. Kim SB, Je BK, Lee KY, Lee SH, Chung HH, Cha SH. Computed tomographic differences of pyogenic liver abscesses caused by *Klebsiella pneumoniae* and non-*Klebsiella pneumoniae*. *J Comput Assist Tomogr* 2007;31:59-65.
17. L Kristopher Siu, Kuo-Ming Yeh, Jung-Chung Lin, Chang-Phone

- Fung, Feng-Yee Chang. *Klebsiella pneumoniae* liver abscess: a new invasive syndrome, *Lancet Infect Dis* 2012;12:881-87.
18. Lin Y, Wang F, Wu P, Fung C, *Klebsiella pneumoniae* liver abscess in diabetic patients: association of glycemic control with the clinical characteristics, *BMC Infectious Diseases* 2013, 13:56/1186/1471-2334-13-56.
19. Yu WL, Chuang YC, Invasive liver abscess syndrome caused by *Klebsiella pneumoniae*, *UpToDate*, 02-05-14.